Therapeutics, Pharmacology and Clinical Toxicology
Vol XX, Number 1, March 2016
Pages: 40 - 43

CASE REPORT

AN OVERLOOKED AETIOLOGY OF CHRONIC ARTHRITIS IN CHILDREN

Iagaru N.[1], Olteanu B.[2]

[1] *Univestity of Medicine and Pharmacy "Carol Davila", Bucharest, Romania*
[2] *Children Clinical Emergency Hospital Bucharest, Romania*

Abstract. TB arthritis is a rare, insidious chronic mono-arthritis resulting in extremely serious destruction of joints and bones. Usually, the possibility of TB arthritis is suggested by family infectious or environmental contact with TB and a positive Test at PPD. The Objectives. Are to discuss about a forgotten etiology of monoarthritis in pediatric patients. The author presents the case of a teenager girl (16 ½ years old) with chronic arthritis of the wrist treated for 6 months in other hospitals, at the onset as acute rheumatic fever and then, as juvenile idiopathic arthritis, oligoarthritis subtype. Although no infected family or environmental contact is known, no predisposing factors, and pulmonary TB are absent, the evolution refractory to treatment with severe joint damages demands a Quantiferon TB Gold Test that comes positive. Surgical evacuation of pus and quadruple tuberculostatic therapy had a favourable outcome with *restitution ad integrum.*

Keywords: monoarthritis, TB, teenager

Background

TB arthritis is rare in Europe and North America (1-3% of the overall TB forms).[1,2] TB's reoccurrence represents a global phenomenon for the last two decades having as enabling causes immunosupressive therapy, chemoresistant strains and HIV infection. Identifying oligoarticular juvenile idiopathic arthritis by differential diagnosis can be quite difficult (1) as it is the most frequently mistaken diagnosis due to misleading common clinical signs.[3, 4, 5] TBC aetiology must always be considered prior to chronic monoarthritis due to the devastating sequelae that can actually be (and must be) avoided.

Case presentation

Female patient aged 16 years and a half, from a family living in the urban area, with an average socio-economic income, insignificant therapeutic and diseases history, complete vaccination scheme based on the National Immunization Programme, without known family infectious contacts, accesses the services of our clinic for the establishing of diagnoses.

History

At the age of 16, the teenager with a previous stable health status presented pain and *functiolaesis* in the left wrist that persisted for two months, starting with 06.04.2012. For six months the patient was investigated and treated in several clinics that hereafter will be referred to with numbers, out of deontological reasons. Two months after the onset of pain, the accentuated discomfort determined the family to go to Clinic number 1 (10-20.06.2012) where she received the diagnosis "Left hand arthritis", according to the discharge papers. Treatment consisted in Dexamethasone 8mg/day for five days along with unspecified physiotherapy procedures. Evolution was unfavourable leading to an extensive swelling in the left hand ("the size of a boxing glove") that was also warm, painful, of red-purplish colour. (Fig. 1)

Fig.1. Red-purplish, warm swelling in the left hand

Furthermore, the X-ray was interpreted within normal limits; increased acute phase reactants and ASLO

Nicolae Iagaru
e-mail: nicolae.iagaru@gmail.com

value was 2296 ui/mL. Corticotherapy was carried out with Methylprednisolone (MP) i.v. 125mg/day for 4 days, followed by a partial relieve in the swelling and in the joint pain. Considering that ASLO titre was still increased (3000 u.i/mL), admission in Clinic number 2 became necessary, namely on a cardiology ward (20.06-03.07.2012). Here, the patient was diagnosed with acute articular rheumatism. She received: Penicillin G i.v. 4 times daily X 10 days, followed by prophylaxis with Moldamin 1.200.000 u i.m/week. However due to continuous pain in the wrist, the patient was referred to Clinic number 3- the Rheumatology Department (23-27.08.2012). Diagnosis: juvenile idiopathic arthritis, Oligoarthritis Subtype. Adminsitration of MP i.v. 125 mg/day X 3 days was resumed, followed by Medrol 8mg/day (2mg every two days starting with 15.09.2012) associated with sulfalazine (SSZ) 2g/ day and Moldamin 1.2.000.00 ui/ week, i.m determined by an ever increased ASLO titre (500 ui/mL). The laboratory data suggested: FR, ANA, anti-CCP (cyclic citrullinated peptide), LE cells (lupus erythematosus) and C3 with no significant changes. Her prolonged unfavourable evolution determined the admission in Institute for Mother and Child Care "Alfred Rusescu" (IOMC) at 24.09.2015.

Physical examination: Female patient, aged 16 ½, afebrile, unaltered general state, good nutrition status (56Kg; 167cm; BMI 20,44). The left wrist showed a discreet swallowing, warm at palpation, with pain and obvious *functiolaesis.* Palmar skin is mottled, hyperhidrotic. Furthermore, muscle atrophy is obvious in the thenar and hypothenar muscles and the interosseous muscles of the left forearm (Fig. 2).

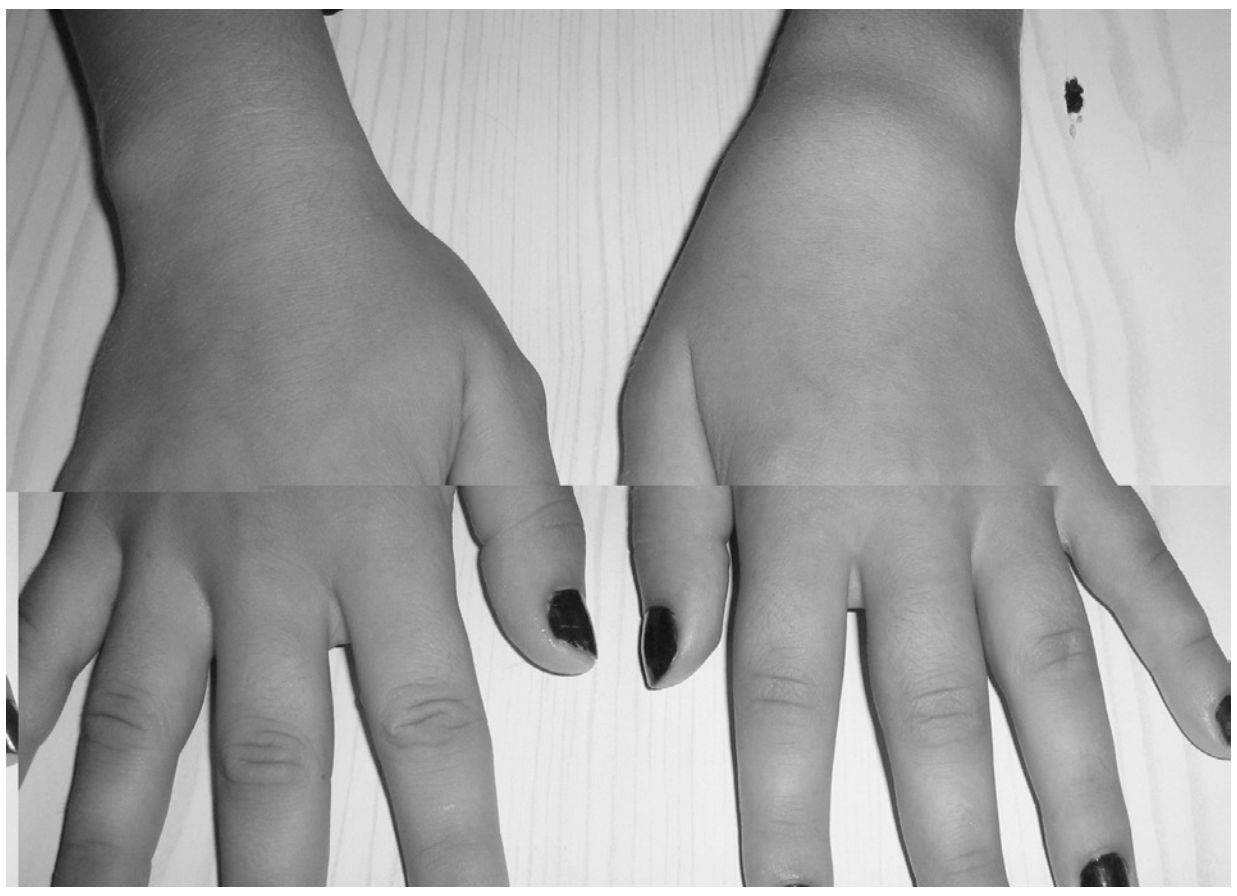

Fig.2. Muscle atrophy in the left hand and forearm

No changes were observed in the remaining joints, enthesis and muscles. CHAQ (*Childhood Health Assessment Questionnaire*):10. Visual analogue scale as assessed by the patient (SVAp): 40. The rest of the physical examination on systems and equipments was normal.

Laboratory results: Acute phase reactants: VSH 7mm; CRP 0.09mg/dL; Fibrinogen: 306mg/dL; normal WBC: 8200/mmc; normal CBC; negative Rheumatoid factor; Antinuclear antibodies (ANA) 7u (N <20u); negative DNA double stranded (dsDNA) antibodies; Anti-Scl-70 antibodies; negative anticentromere antibodies; ASLO 333ui/mL; negative Lyme Diseases blood test confirmed by Elisa (IgM and IgG).

Radiography of the left radiocarpal joint, at 4 months (24.08.2012) and 6 months (24.09.2012) from onset emphasized the following: "Diffuse demineralisation of the left carpal and metacarpal bone. The carpal bones appear smaller, with geode and eroded cortical contours, especially on the intercarpal ligaments". (Fig. 3).

Fig.3. Diffuse demineralisation of the left carpal and metacarpal bone. The carpal bones appear smaller, with geode and eroded cortical contours, especially on the intercarpal ligaments

MRI examination taken at 16.10.2012 revealed: "Carpal bone erosion especially in the unciform, capitate and trapezoid bone with damage in articular surface. (Fig.4). Pulmonary radiography: no pleuropulmonary lesions under evolution. IGRA Quantiferon TBC Gold test):15,619 UI/mL, "positive result" (negative < 0, 35).

Fig.4. MRI: Carpal bone erosion especially in the unciform, capitate and trapezoid bone with damage in articular surface

In the end, clinical evolution, radiological changes, MRI exam and, especially, the positive Gold Quantiferon determined the diagnosis: TB arthritis. The patient was transferred to a specific medical unity where she underwent surgery for drainage of pus. Also further investigation was performed (histopathological and bacteriological examination) which confirmed the aethology of TB arthritis. Quadruple tuberculostatic therapy was started with isoniazid/HIN, rifampicin/ RIFA, ethambutol, pyrazinamide/PZA, monitored by specialists from the phtiziology network which led to favourable evolution with *restitutio ad integrum*.

Discussions

Tuberculosis arthritis is usually monoarticular with general impact on large articulations- in the hip and knee. As with our case, the illness manifests through swelling, local sensitivity, local feeling of warmth, pain, progressive *functiolaesis*, reduced mobility in the joints, weight loss or loss of appetite.[1,2] Hence, joint infection occurs through haematogenous dissemination of *Mycobacterium tuberculosis* (MT) from a neighbouring osteomilitis lesion. Isolated monoarthritis caused by MT, in the absence of a pulmonary clinical disease is extremely rare. Usually, an infectious TB contact from the family or living environment and a positive TST test suggest the occurrence of TB arthritis. Most often, the analysis of the synovial fluid does not provide sufficient characteristic traits of TB synovitis, which could constitute a valid diagnostic rationale.[6] On the other hand, the presence of caseous granuloma in histopathology examination of the synovial fluid, even without microbiological confirmation is suggestive for TB arthritis. Although cultures on Lowenstein-Jensen medium from the synovial fluid are positive for a quarter of the overall cases,[1] biopsy and cultures from the synovial membrane are preferred when confirming a diagnosis, the final diagnosis relying on MT isolation. Still, TB arthritis is a paucibillary infection, with a possibility for negative Ziehl-Neelsen stain and cultures. Hence, PCR (polymerase chain reaction) may be a more reliable assay. In USA, only 28% of children diagnosed with tuberculosis have positive cultures compared to 90% of adults.[7, 8] Reliability of PCR compared to cultures, remains however difficult to assess. PCR has a reduced sensitivity but an increased specificity to detect MT (95-98% when cultures are positive and 95% respectively, when they are negative.[6, 7, 8]

Pathogenesis. In children, TB arthritis usually occurs as a result of osteomielitis crossing the epiphyseal plate, either through subsynovial vessels to the joint, or indirectly through metaphyseal lesions which erode the bone through the articular space.[6, 10, 11] This "transphyseal" mechanism is specific for TB and fails to occur in septic arthritis (pyogenic) (idem). In children older than one year and a half, transphyseal vessels disappear hence dissemination to epiphysis and joint turn into an abnormal mechanism.[6, 10, 11] Subsequent to the localisation in the synovial joint or metaphysis, a remarkable joint effusion appears along with a thickened synovial membrane. The granulation tissue causes erosions at the level of the bone and on the free surface of the articular cartilage. Left untreated, TB arthritis can cause other erosions that can progress to the destruction of articular surfaces. As a result of the cartilage and bone's damage, sequestrums form, affecting both sides of the joint ("*kissing sequestrum*"), the extension of lesions to the periarticular soft tissues and generating cold abscesses.[6] Radiological changes became visible only after a latent period of approximately 3-4 weeks.[6] During early stages, joint and soft tissues swellings occur along with articular effusion. On the other hand, at advanced stages "Phemister's triad" develops: narrowing of joint space, juxta-articular osteopaenia, peripheral osseous erosions. A relative upkeep of the articular space is a classical trait and is due to the absence of proteolytic enzymes from M. tuberculosis.[6] In children a delayed periosteal reaction occurs in the absence of sclerosis and/or periostitis, conditions that are characteristic to adults. Late stages manifest through severe joint destruction and possible sclerosis and fibrous ankylosis.

MRI investigation (Fig.4) usually reveals early changes this rendering it a priority in imaging. Articular effusion in T2 features hyperintense. Detritus, septation and hemosiderin deposits caused by bleeding are hypointense in both T1 and T2. Synovial thickening appears as a weak or median signal in T2 but is hyperintense in T1 due to the caseous material, atypical for other bone infections (a highly useful reference for diagnosis).[6, 11, 12]

Differential diagnosis: Anamnesis, the clinical and laboratory data exposed throughout this case presentation indicate chronic inflammatory arthritis (onset- 6 months prior to presentation at our clinic). In consequence, either septic or traumatic arthritis (hemathrosis) or acute articular rheumatism (absence of Jones criteria, postsrteptococcal disorder- unseen for over two decades) lack any fundament. Taking into consideration highly elevated ASLO titres, the only plausible cause for reactive arthritis would have been poststreptococcal reactive arthritis (ARPS): acute onset, persistent monoarthritis, absent response to nonsteroidal anti-inflammatory drugs (NSAIDs). The absence of any response to steroids and antibiotic based treatment as well as the aggravating joint inflammation with severe bone erosion cast away this suspicion. Under these circumstances, high increase in ASLO titre constitutes a particularity of the case which can cause misinterpretation in terms of arthritis aetiology. The overlapping streptococcal infection must have been random. In what concerns juvenile oligoarticular idiophatic arthritis, neither the onset at the age of 16, absent response to steroids and NSAIDs or unusual and severe osteoarticular destruction are defining for this disease. Introduction of biological treatments in AIJ (special mention for Infliximab) draws the attention to the risk of TB occurrence, even joint tuberculosis.. [7] Test results for Borrelia, quite a "fashionable" investigation for the last couple of years, came back negative.

Conclusions

The case presentation insists on the diagnosis difficulties for isolated TB monoarthritis when infectious contacts and pulmonary disorder are absent. Although the data on our patient suggest, in a very low degree, a rheumatic disorder this is in fact the most common diagnosis misinterpretation reported by literature, especially monoarticular arthrtis. In areas endemic to tuberculosis, paediatricians must be informed on the possibility that chronic arthritis in children, especially older ones, could have a specific TB aetiology rather than an autoimmune one. (AIJ). Early TB diagnosis relies on significant suspicions accompanied by the notion of infectious contact, TST (Mantoux tuberculin skin test) to PPD conversion or positive Quantiferon. The confirmation diagnosis requires the demonstration of monoarthritis

References

1. Laxer RM, Lindsley CB. Tuberculous Arthritis. *Textbook of Pediatric Rheumatology, Edited by JT Cassidy et al., Sixth Edition, Saunders Elsevier* **2011,p 565.**

2. Derek Rajakumar, Alan M Rosenberg. Mycobacterium tuberculosis monoarthritis in a child. *Pediatric Rheumatology* **2008, 6:15 doi:10.1186/1546-0096-6-15.**

3. Al-Matar MJ, Cabral DA, Petty RE. Isolated tuberculous monoarthritis mimicking oligoarticular juvenile rheumatoid arthritis. *J Rheumatol.* **2001 Jan;28(1):204-6.**

4. Finsterbush A, Husseini N, Mann G, Shaul J. Pitfalls in the diagnosis of tuberculous arthritis. *Harefuah.* **1991 Jan 15;120(2):62-6(Abstr).**

5. Rabesalama SS, Rakoto-Ratsimba HN, Razafimahandry HJ. Tuberculous arthritis of the wrist: a case report. *Chir Main.* **2009 Sep;28(4):243-6. doi: 10.1016/j.main.2009.04.006. Epub 2009 May 23(Abstr).**

6. E.S. Ling Mah, S.I. Bux: Tuberculous synovitis of the knee with unusually thick synovial granulation tissue: A Case Report. *The Internet Journal of Orthopedic Surgery.* **2007 Volume 6 Number 2).**

7. W. Armbrust , S. S. M. Kamphuis , T. W. F. Wolfs , T. J. W. Fiselier, et al. Tuberculosis in a nine-year-old girl treated with infliximab for systemic juvenile idiopathic arthritis. *Rheumatology* **Volume 43, Issue 4 Pp. 527-529.**

8. American Thoracic Society and the Centers for Disease Control and Prevention."Diagnostic Standards and Classification of Tuberculosis in Adults and Children", *American Journal of Respiratory and Critical Care Medicine,* **Vol. 161, No. 4 (2000), pp. 1376-1395.**

9. Mohammed J. Al-Sayyad, L.A. Abumunaser. Tuberculous arthritis revisited as a forgotten cause of monoarticular arthritis. *Ann Saudi Med.* **2011 Jul-Aug; 31(4): 398–40.**

10. Parmar H., Shah J., Patkar D. et al.: Tuberculous arthritis of the appendicular skeleton: MR imaging appearances. *European Journal of Radiology* **2004; 52:300-309.**

11. Teo H.E. L., Peh W.C.G.: Skeletal tuberculosis in children. *Paediatric Radiology* **2004; 34: 853-860.**

12. De Vuyst D., Vanhoenacker F., Gielen J., Bernaerts A., de Schepper A.M.: Imaging features of musculoskeletal tuberculosis. *European Journal of Radiology* **2003; 13: 1809-1819.**