



STATINS AND THE SKIN

Adina M. Dobrițoiu¹, D. G. Forsea²

¹ "Carol Davila" University of Medicine and Pharmacy, Bucharest

² Dermatology Department, Colentina Hospital

Abstract. Statins are by far the most widely used class of lipid-lowering drugs and they are the class of choice for LDL-C reduction. Their cutaneous side effects reported in medical literature so far can be classified into four types: autoimmune reactions, reactions due to dryness of the skin, severe reactions like -DRESS, and allergic reactions. Recent research has proven that statins also have immunomodulatory activities and thus they can be used in the treatment of several immunological conditions which are characterized by a Th1 immune response. Statins are reported to be effective against psoriasis, to improve altered wound repair in diabetic skin, to decrease the incidence of skin cancer or to decrease fibroblasts activities in systemic sclerosis. The recently reported beneficial properties need further investigations.

Keywords: statins, adverse reactions, immunologic properties, psoriasis, systemic sclerosis.

Generalities

Discovery

Statins are by far the most widely used class of lipid-lowering drugs. They were discovered by Akira Endo. He was the first who isolated mevastatin from the mould *Penicillium citrum* in 1973. He and his colleagues demonstrated that this novel compound lowered serum cholesterol levels by inhibiting the rate-limiting enzyme in cholesterol biosynthesis- HMG-CoA reductase, the enzyme that converts HMG-CoA to mevalonate. Only after the 1990s, clinicians throughout the world truly understood the importance of this new drug [1,2].

Pharmacokinetics

Nowadays this class of drugs includes not only natural but also synthetic drugs: lovastatin, simvastatin, pravastatin, atorvastatin, fluvastatin, cerivastatin. All of them have the same effects on lipid profile. Their structures reveal some small

but important differences and these translate into pharmacokinetic differences. The most notable such difference is that pravastatin is unique amongst the statins to date in being water soluble. That is why it is not metabolized by the cytochrome P 450 as are all the others. Atorvastatin has the longest plasma half-life [1,2]. (figure 1, 2)

Mechanism of action

Their mechanism of action is by inhibiting the rate-limiting enzyme in cholesterol biosynthesis- HMG-CoA reductase. They inhibit the HMG-CoA reductase which is the rate-limiting step in cholesterol biosynthesis; inhibition of this enzyme decreases cholesterol synthesis. This determines a low intracellular cholesterol level and up-regulates the LDL receptors to import more cholesterol from the plasma [1,2]. Statins' interference with cholesterol biosynthesis leads to the depletion of intermediate substances called isoprenoids, which have been shown to activate inflammation via intracellular second messenger system. This mechanism explains the antiinflammatory and immunomodulatory effects of statins [3].

Side effects

Statins usually cause mild problems like: dys-

Adina Dobrițoiu

e-mail: adina_dobritoiu@yahoo.com

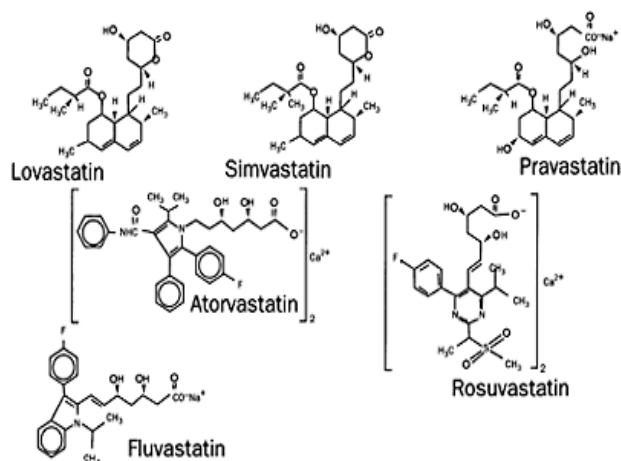


Figure 1. The structures of the marketed statins compared

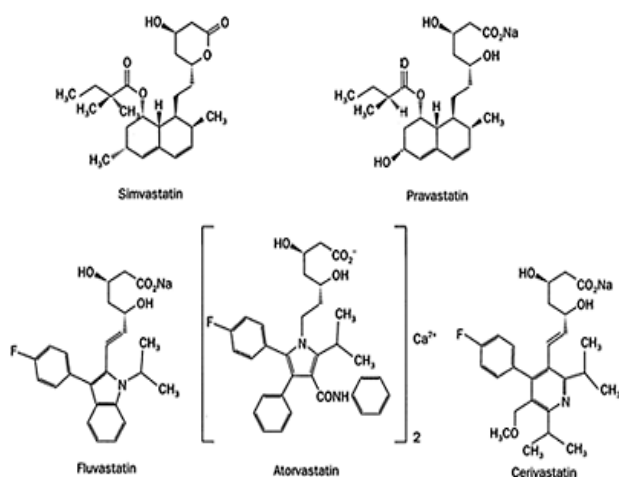


Figure 2. Semi-synthetic and synthetic statins

pepsia, headaches, fatigue, and muscle or joint pains. They can determine elevation in liver transaminases (ALT and AST). Severe myopathy and even rhabdomyolysis can occur rarely with statin treatment (*remember Baycol –cerivastatin recently withdrawn*). Recent studies reveal that there is a slightly increased risk of diabetes among statins treated patients. Cutaneous side effects are not very frequent but they deserve to be mentioned [1,2].

A small study made on 20 patients with suspected drug induced skin reaction sustained the idea that the IFN-gamma release test can detect cutaneous adverse effects of statins. The reliability of the test was strengthened by prompt improvement following elimination of the suspected drug in the majority of patients [4].

Cutaneous side effects

Cutaneous side effects of statins can be divided into four types or reactions:

I. Autoimmune reactions:

A. Collagenosis

- Systemic lupus erythematosus (SLE)
 - Subacute cutaneous lupus erythematosus (SCLE)
 - Dermatomyositis (DM)
 - Polymyositis (PM)
- ##### B. Bullous disease
- Lichen planus pemphigoides
 - Linear IgA bullous dermatosis
- ##### C. Lichenoid reactions
- Lichenoid drug eruption

II. Reactions due to dryness of the skin (modifying skin cholesterol):

- Ichthyoses
- Generalized eczematous skin rash
- Cheilitis

III. Severe reactions

- DRESS (drug reaction with eosinophilia and systemic symptoms)
- Acute generalized pustulosis
- Eosinophilic fasciitis

IV. Occupational disease

- Occupational contact dermatitis

I. Autoimmune reactions:

A. Collagenosis

Systemic lupus erythematosus

Statin-induced lupus-like syndrome is characterized by the long delay between the beginning of therapy and skin eruption. In most cases, symptoms appeared only many months or even years after starting statin therapy.

Two types of drug-induced LE have been reported with statin therapy: SLE and SCLE. SLE is the most frequent form and is characterized primarily by serositis and systemic manifestations. Skin lesions are rare [5]. Antihistone antibodies are found in less than 50% of patients. SCLE is the second most common form of drug-induced LE. Skin lesions are almost always present and consist of typical photosensitive, scaly, annular erythematous lesions. Anti-Ro/SSA antibodies are frequently found. Histopathology examination of the skin reveals keratinocyte alterations (apoptotic cells) with vacuolization of basal cells and perivascular lymphocytic infiltrations in the upper dermis.

In patients with statin-induced SLE, systemic immunosuppressive therapy was usually required but in statin-induced SCLE topical corticosteroids were usually sufficient. Recovery after cessation of the offending drug was very slow. ANA may persist for many months after drug discontinuation. [5,6,7].

Dermatomyositis

In dermatomyositis induced by statins, muscular symptoms are usually associated with typical skin lesions: facial heliotrope rash, violaceous erythema

of the trunk, and characteristic papules of Gottron with periungual telangiectasia [5]. There also is an elevation of plasma CK levels. High ANA levels are usually seen and still positive many months after clinical recovery. Anti Jo-1 antibodies can be present. Immunosuppressive therapy may be necessary in DM and PM to avoid life-threatening complications. Usually, despite discontinuation of the drug, symptoms progress. Statins can also induce toxic myopathy. Muscle biopsy is required to distinguish these muscular disorders. The presence of inflammation is the histological hallmark of DM and PM. Perifascicular T-lymphocytic infiltration is generally observed. Muscle fibres may undergo degeneration and necrosis [5,8].

B. Bullous disease

Lichen planus pemphigoides

One case of lichen planus pemphigoides was described by Stobner, in a male patient treated with simvastatin for hypercholesterolemia; the diagnosis was supported by clinical, histological data: he had a pruriginous bullous lichenoid eruption. The histological examination and direct immunofluorescence confirmed the diagnosis. Western blot analysis revealed antibodies against BP 180 kDa antigens. All the lesions progressively disappeared after stopping the simvastatin [5].

Linear IgA bullous dermatosis

Konig and others reported a case of IgA bullous dermatosis in a patient who developed the skin lesions shortly after beginning the treatment with atorvastatin. In Western blotting analysis they detected IgA and IgG class antibodies targeting a 97-kd protein [9].

C. Lichenoid reactions

Lichenoid drug eruptions are uncommon and can be difficult to differentiate from idiopathic lichen planus due to similarities in clinical and histological appearance. A long list of drugs was reported to induce lichenoid eruptions and statins are among them with a very low incidence.

Two cases of lichenoid eruption after the treatment with pravastatin; both patients recovered after stopping the drug.

The first case is that of a female patient who presented with diffuse and numerous pigmented macules on her face and upper back. Histopathologic examination of a skin punch biopsy of the rash showed a lichenoid dermatitis. Cessation of pravastatin resulted in gradual fading of the pigmentation [10].

The other case is that of a patient whose lichenoid lesions developed after initiation, resolved on discontinuation, and reappeared on rechallenge with pravastatin therapy [11].

Also reported was a case of lichenoid eruption developed after simvastatin therapy. It is the case of a 57 year-old woman who developed specific lichenoid eruption four weeks after beginning the hypolipemiant treatment [12].

II. Reactions due to dryness of the skin

Epidermal cholesterol synthesis has been shown to be essential for maintaining the cutaneous barrier function. There are some assumptions that skin cholesterol concentrations are lowered after prolonged treatment with cholesterol lowering drugs. The dry skin, the alteration of the permeability of the skin barrier induced by statins can manifest as cheilitis, eczemas, ichthyosis. But there are controversial opinions about the effects of HMG-CoA inhibitors on skin cholesterol. Most of them confirm the fact that statins do not have big influences on skin cholesterol [13,14].

Ichthyosis

There is one case reported of a 52 year-old woman who presented a localized acquired ichthyosis on her arms and forearms after beginning treatment with pravastatin [15].

Cheilitis

Some clinicians reported patients who experienced cheilitis after beginning treatment with simvastatin for hyperlipidemia. The rash resolved after discontinuation of medication and subsequent treatment with topical moisturizers and topical corticosteroids [16].

Eczematous generalized skin rash

An article described the cases of three patients who developed a generalized eczematous skin rash under treatment with simvastatin and pravastatin for hypercholesterolemia. The authors propose that statins can affect skin barrier function following inhibition of cholesterol biosynthesis [17].

III. Severe reactions

DRESS

Drug rash with eosinophilia and systemic symptoms (DRESS) syndrome is a severe adverse drug reaction characterized by skin rash, fever, lymph node enlargement and internal organ involvement which starts within 8 weeks after the initiation of the therapy. Aromatic anticonvulsants and sulphonamides are the most common causes.

This was the case for an old woman who developed DRESS 6 weeks after having started atorvastatin. She presented all the clinical signs and symptoms of the syndrome: febrile skin rash with oral mucosa involvement and systemic symptoms (fever, abdominal pain, diarrhoea, polyarthralgia and adenomegaly). Blood tests showed hypereosinophilia, inflammatory syndrome and anicteric cholestasis without cytolysis [18].

Acute generalized exanthematous pustulosis

Acute generalized exanthematous pustulosis is an acute pustular eruption occurring most commonly after drug ingestion. It is a self-healing condition with spontaneous cure after discontinuation of the causative drug.

There was a case reported by T.Oskay and L. Kutluay. A 57 year-old man who developed an erythematous eruption with numerous nonfollicular pustules associated with high leukocyte levels shortly after beginning treatment with simvastatin. A positive rechallenge test confirmed the diagnosis of AGEP induced by simvastatin [19].

Eosinophilic fasciitis

Eosinophilic fasciitis is a rare inflammatory condition of the subcutis and muscles characterized by symmetrical painful swelling and induration of the extremities. The etiology is unknown but sometimes it has been associated with drug exposures.

The case of an old woman who developed symptoms of eosinophilic fasciitis soon after commencing atorvastatin treatment was reported. A deep biopsy was performed to confirm the clinical supposition of the diagnosis. Immunosuppressive treatment was needed. It is important to consider statins as a possible cause when diagnosing patients with eosinophilic fasciitis [20].

IV. Occupational dermatitis

Allergic contact dermatitis is a delayed type hypersensitivity reaction caused by skin contact with an allergen. Sensitization is required and allergy is specific to a particular chemical.

There are two cases reported of occupational airborne contact allergy to simvastatin affecting the face and neck only. Both cases were working in the pharmaceutical industry in quality control in simvastatin synthesis [21].

New achievements about statins

Laboratory and clinical evidence is certainly accumulating to the effect that individual statins may possess benefits beyond their cholesterol lowering capability. These ancillary effects of statins regard: plaque stabilization, endothelial function, cellular immunity, anti-inflammation, lipoprotein oxidation, rheology and blood coagulation, glucose intolerance [1].

The first observation was that statins (simvastatin in 4S and pravastatin in CARE, WOSCOPS) influence atheroma stability and thrombogenicity by mechanism of action additional to those influencing LDL deposition in plaque [2].

In a prospective randomized trial on pravastatin therapy in heart transplanted patients it was observed that episodes of acute rejection were re-

duced and graft survival prolonged. As explanation, the reduction of natural killer cell cytotoxicity was proposed, an action synergistic to cyclosporine [1,2].

Another important observation during randomized study was that pravastatin reduction of C-reactive protein was not related to the magnitude of lipid levels.

The mechanisms of these ancillary effects are still to be explored. The primary role of statins is to inhibit the HMG-CoA reductase, decreasing cholesterol synthesis. In inhibiting this pathway they also modulate levels of geranyl-pyrophosphate and farnesyl-pyrophosphate, which are involved in the control of proteins through prenylation and have role in morphogenesis. Mevalonate, the product of HMG-CoA reductase, is a precursor of not only cholesterol but of a range of other important molecules involved in function as cellular respiration, signal transduction and nitric oxide production [3].

Some of these new properties can be used in the treatment of some skin diseases autoimmune

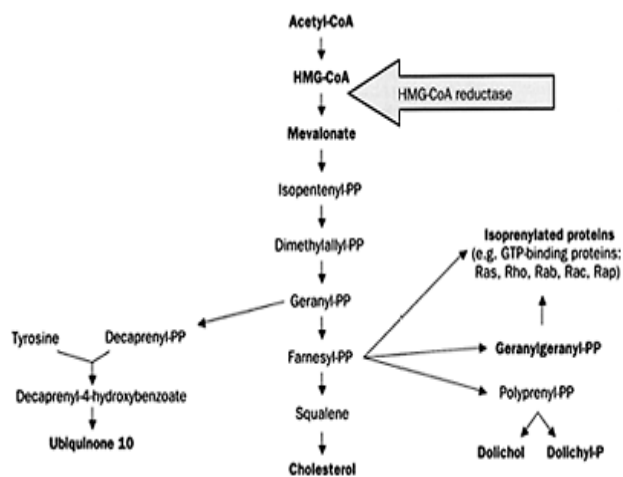


Figure 3. Cholesterol synthesis pathway

Schematic representation of the mevalonate pathway in human cells

diseases, collagenoses, diabetes skin manifestations, skin radiation, psoriasis.

1. Autoimmune diseases

Studies have shown that statins have immunomodulatory activities due to interfering with the mediators of the immune system. They down-regulate the expression of intercellular adhesion molecule-1 (ICAM-1), monocyte chemotactic protein-1 (MCP-1) and lymphocyte function-associated antigen-1 (LFA-1), on leucocytes and endothelial cells. They inhibit the activation of lymphocytes and their infiltration into the inflammation sites. This mechanism is explained by binding to LFA-1, they interfere with ICAM-1-LFA-1 interaction, which is crucial for activation of lymphocytes by antigen-presenting cells, ingress of leucocytes into

the inflammation sites and immunologic cytotoxicity. They block expression of several proinflammatory cytokines such as tumour necrosis factor- α and interferon- γ in macrophages.

Statins downregulate the expression of adhesion molecules. Statins inhibit the inducible expression of major histocompatibility complex class II in several cell types including macrophages and downregulate the expression of T-helper-1 (Th1) chemokine receptors on T cells. These agents inhibit the proliferation of immunocytes and the activation of natural killer cells. Statins block the induction of inducible nitric oxide synthase and possess antioxidant effects [22].

Statins may be beneficial in several immunological conditions such as *allergic asthma, multiple sclerosis, rheumatoid arthritis, alopecia areata, vitiligo, lichen planus, subacute cutaneous lupus erythematosus, erythema multiforme, psoriasis, bullous pemphigoid, systemic sclerosis, mycosis fungoides, toxic epidermal necrolysis and Behcet's disease* which are characterized by a Th1 immune response. [1,2,16]. The efficacy of simvastatin in treating inflammatory arthritis and allergic asthma in mice models was demonstrated.

Statins such as simvastatin have an acute anti-inflammatory dose-dependent activity comparable to indomethacin. They reduce polymorphonuclear leukocyte infiltration. Simvastatin reduces leukocyte-endothelial cell interactions via down regulation of p-selectin expression on the microvascular endothelium. These informations were observed in an experimental model of acute local inflammation, the carrageenan induced foot edema [23].

Statins also reduce reactive oxygen species from neutrophils so they can be effective for the treatment of neutrophilic disorders like Sweet's syndrome or pyoderma gangrenosum.

2. Radiation induced skin damage

Statins have been reported to preserve endothelial function through their antioxidant and anti-inflammatory activities.

In a study on mice it was proven that pravastatin limits the maximal level of blood CCL2 and CXCL1 and downregulation of eNOS, after a radiation dose. It was observed that the migration of inflammatory cell in tissues was inhibited due to downregulation of expression of inflammatory adhesion molecules such as E-selectin and intercellular adhesion molecule-1. Pravastatin may be a good therapeutic approach to prevent or reduce radiation-induced skin damage [24].

3. Psoriasis

Statins also have effects on psoriasis. Statins inhibit leukocyte function antigen-1 (LFA-1) whereas selective LFA-1 blockade has been successfully used to treat psoriasis. Statins reduce cytokine produc-

tion by T helper 1 cells (Th1) with the increased Th1 response being one of the key mechanisms of persistent skin inflammation in psoriasis. Statins may be of particular value in the population of psoriasis patients that has increased risk of cardiovascular disease [25].

It is important to mention that psoriasis and atherosclerosis have similar histological characteristics involving T cells, macrophages and monocytes. Both diseases are characterized by the extravasation of T cells through the epithelium.

Patients with psoriasis have an increased cardiovascular risk profile compared with the general population. Recent control studies have proved that the presence of psoriasis is associated with an increased risk of arterial hypertension, coronary heart disease, hyperlipidemia, obesity and type II diabetes. This association can be explained by the effects of chronic inflammatory changes, particularly the infiltration of T cells and subsequent secretion of pro-inflammatory cytokines [26].

4. Collagenosis

Systemic sclerosis is usually associated with Raynaud's phenomenon and digital ulceration is a serious complication. The treatment of this ulceration is very difficult. Statins can minimize vascular injury due to their pleiotropic effects on endothelial function.

Given the safety and relative low cost and good patient tolerability for this class of drugs, statins may aid in treating Raynaud's phenomenon and digital ulcers in SSc patients, improving their medical condition. [27].

Simvastatin also downregulates transforming growth factor β , the most important cytokine in producing fibrosis and depresses the collagen I synthesis.

5. Diabetic skin manifestation

As it was said before statins have different effects beyond cholesterol reduction and stimulate angiogenesis. A small study on mice investigated the effect of simvastatin in diabetes-related healing defects. It was shown that simvastatin enhances VEGF production and ameliorates impaired wound healing in diabetic mice. So simvastatin has a potential application in diabetes-related wound healing disorders [28].

In another study, in an experimental model of diabetes, it was shown that pravastatin may determine up-regulation of eNOS and NO expression, improving wound healing in diabetes [29].

6. Candida infections

Inhibiting HMG-CoA reductase, statins may interfere with the biosynthesis of ergosterol, the major sterol of the yeast cell membrane. A small study showed that in the absence of fungicidal activity, simvastatin's interruption of a critical step

in an essential metabolic pathway, highly conserved from yeast to man, has unexpected effects on biofilm production by a eukaryotic pathogen [30].

7. Melanoma and other skin cancers

Statins and cancer is a controversial topic. Fas-mediated apoptosis is an essential mechanism protective against skin cancer. Cholesterol depletion from membrane causes the Fas activation and apoptosis of keratinocytes. This theory may explain the antiproliferative and proapoptotic properties of statins proved by some in vitro studies.

The principal molecular abnormality in basal cell carcinoma pathogenesis is a defective activation of the Hedgehog signals pathway. Statins may prevent the formation of BCC tumors inhibiting the final step in this intracellular pathway. They can be used as a chemopreventive drug in Gorlin's syndrome.

There are some studies trying to explore the effect of statins on melanoma outcomes. The results were divergent. Some suggests protective effects of statins on melanoma progression other do not validate this possibility. Statin treatment is unlikely to prevent melanoma development at standard doses but higher doses of statins may have a role to play in adjuvant therapy by inhibiting growth and invasion of melanoma cells [31,32,33,34,35].

Discussions

All this recent research sustains the idea that statins can be used as therapeutic option for diseases other than dyslipidemia. Statins can induce some skin disorders like: collagenosis, bullous dermatoses, eczematous reactions or severe reactions like DRESS. These are all the skin side effects of statins that I found searching the literature (using Pubmed). There is just one single review article in the literature regarding cutaneous side effects of statins presented by B Noel in 2007. He described 28 cases of autoimmune disease induced by statins treatment [5]. Searching the literature I found a few other cases with different types of skin reaction and I tried to organize them in the table presented above (table I). I myself found a new case of AGEPE (acute generalized exanthematous pustulosis) induced by statins. That is the case of 67 year-old man that I have presented in a prior article [36].

There are many laboratory researches that confirm that statins have important immunomodulatory and anti-inflammatory properties but the clinical studies are only a few. A recent study was a clinical proof of the efficiency of simvastatin (40mg/day) in improving the evolution of a case of refractory rheumatic disease. There are two patients with severe, refractory forms of alopecia areata who improved after treatment with simvastatin and ezetimibe associated with intralesional corticotherapy. There is another case of universalis alopecia with a good

response to the same therapy [37,38].

In another pilot study, seven patients with psoriasis improved their clinical appearance after receiving simvastatin 40 mg in association with topical therapy [25].

New case-control studies are needed in order to sustain this new therapeutic option of statins for autoimmune and inflammatory diseases.

Conclusion

Statins use is "in fashion" nowadays. Skin eruptions induced by statins are still rare but it is important to recognize and treat them correctly.

We noticed the beneficial role of statins in treating certain skin diseases. The ancillary benefits of statins are just at the beginning of their medical practice. The time will be the one who will discern but they seem to be a benefic key in the treatment of certain skin diseases.

All the data presented in the article were found on the internet (www.ncbi.nlm.nih.gov/pubmed/) and in the virtual library of JEADV (Journal of European Association on Dermato-Venereology) using "statins and skin" as keywords.

„ACKNOWLEDGEMENT: This paper is supported by the Sectoral Operational Programme Human Resources Development (SOP HRD), financed from the European Social Fund and by the Romanian Government under the contract number POSDRU/6/1.5/S/17“.

References

1. **Allan Gaw.** Statins in general practice, **pg. 18-34.**
2. **Allan Gaw.** Statins-the HMG-CoA reductase in prospective, second edition, Allan Gaw, **44-95.**
3. **Chao-Yung Wang, Ping-Yen Liu, J. K. Liao, Pleiotropic effects of statin therapy.** Trends Mol Med 2008, January
4. **Goldberg I, Isman G, Shirazi I, Brenner S,** Interferon-gamma (INF-gamma) release test can detect cutaneous adverse effects to statins, *Int J Dermatol.* **2009 Dec;48(12):1370-5.**
5. **B Noël.** Lupus erythematosus and other autoimmune diseases related to statin therapy: a systematic review, *Journal of European Academy of Dermatology and Venereology* **2007,21, 17-24.**
6. **Srivastava M, Rencic A, Diglio G, Santana H, Bonitz P, Watson R, Ha E, Anhalt GJ, Provost TT, Nousari CH.** Drug-induced, Ro/SSA-positive cutaneous lupus erythematosus, *Arch Dermatol.* **2003 Jan;139(1):45-9.**
7. **Noël B, Panizzon RG.** Lupus-like syndrome associated with statin therapy, *Dermatology.* **2004; 208(3):276-7 (ISSN: 1018-8665).**
8. **Vasconcelos OM, Campbell WW.** Dermatomyositis-like syndrome and HMG-CoA reductase inhibitor (statin) intake, *Muscle Nerve.* **2004 Dec;30(6):803-7.**
9. **König C, Eickert A, Scharfetter-Kochanek K, Krieg T, Hunzelmann N.** Linear IgA bullous dermatosis induced by atorvastatin, *J Am Acad Dermatol.* **2001 Apr;44(4):689-92.**

10. Pua VS, Scolyer RA, Barnetson RS. Pravastatin-induced lichenoid drug eruption. *Australas J Dermatol*. 2006 Feb;47(1):57-9.
11. Keough GC, Richardson TT, Grabski WJ. Pravastatin-induced lichenoid drug eruption. *Cutis*. 1998 Feb;61(2):98-100.
12. Roger D. Simvastatin –induced lichenoid drug eruption. *Clinical and experimental dermatology* 1994;19:88-89.
13. Reiter M, Susan Wirth, Ali Pourazim, Mehrdad Baghestanian, Erich Minar and Robert A. Bucek Statin Therapy Has No Significant Effect on Skin Tissue Cholesterol: *Results from a Prospective Randomized Trial*.
14. Brazzelli V, Distsnte F, Penari G, Berardesca E. Effects of systemic treatment with statins on skin barrier function and stratum corneum water-holding capacity. *Dermatology*. 1996; 192(3):214-6 (ISSN: 1018-8665).
15. Sparsa A. Acquired ichthyosis with pravastatin. *Journal of European Academy of Dermatology and Venereology* 2007;21, 536-578.
16. Mehregan DR, Mehregan DA, Pakideh. Cheilitis due to treatment with simvastatin. *Cutis*,1998 Oct;62(4):197-8.
17. Krasovec M, Elsner P, Burg G. Generalized eczematous skin rash possibly due to HMG-CoA reductase inhibitors. *Dermatology*. 1993;186(4):248-52.
18. Gressier L, Pruvost-Balland C, Dubertret L, Viguier M. Atorvastatin-induced drug reaction with eosinophilia and systemic symptoms (DRESS), *Ann Dermatol Venereol*. 2009 Jan;136(1):50-3. Epub 2008 Nov 28.
19. Oskay T, Kutluay L. Acute generalized exanthematous pustulosis induced by simvastatin. *Clin Exp Dermatol*. 2003 Sep;28(5):558-9.
20. DeGiovanni C, Chard M, Woollons A. Eosinophilic fasciitis secondary to treatment with atorvastatin, *Clin Exp Dermatol* 2005, 31;129-156 ;
21. Laura Pramiguel, Esther Serra, Joan Dalmau, Antonia T Vila, Jose Manuel Mascaro. Occupational contact dermatitis from simvastatin, *Contact dermatitis* 2005, 52, 286-287.
22. Namazi MR. Statins: novel additions to the dermatologic arsenal? *Exp Dermatol*. 2004; 13(6):337-9 (ISSN: 0906-6705).
23. Nezić L, Skrbic R, Dobric S, Stojilkovic MP, Jacevic V, Satara SS, Milvanovic ZA, Stojakovic N. Simvastatin and indomethacin have similar anti-inflammatory activity in a rat model of acute local inflammation, *Basic Clin Pharmacol Toxicol*. 2009 Mar;104(3):185-91.
24. Holler V, Buard V, Gaugler MH, et al Pravastatin limits radiation-induced vascular dysfunction in the skin. *J Invest Dermatol*. 2009 May;129(5):1280-91.
25. Ivan Valeryevich Sherinsky. Efficacy of simvastatin in plaque psoriasis: A pilot study, *J Am Acad Dermatol Volume* 57, nr 3, 529-531.
26. Späh F. Inflammation in atherosclerosis and psoriasis: common pathogenic mechanisms and the potential for an integrated treatment approach. *Br J Dermatol*. 2008 Aug;159 Suppl 2:10-7.
27. Abou-Raya A, Abou-Raya A, Helmii M. Statins: potentially useful in therapy of systemic sclerosis-related Raynaud's phenomenon and digital ulcers, *J Rheumatol*. 2008 Sep;35(9):1801-8.
28. Bitto A , Minutoli A, Altavilla D, Polito F, Fiumara T, Marini H, Galeano M. Simvastatin enhances VEGF production and ameliorates impaired wound healing in experimental diabetes. *Pharmacol Res*. 2008 Feb;57(2):159-69.
29. Laing T, Hanson R, Chan F, Bouchier- Hayes D. Effect of pravastatin on experimental diabetic wound healing. *J Surg Res*. 2010 Jun 15;161(2):336-40. Epub 2009 Feb 21.
30. Liu G, Vellucci VE, Kyc S, Hostetter MK. Simvastatin inhibits *Candida albicans* biofilm in vitro. *Pediatr Res*. 2009 Dec;66(6):600-4.
31. Freeman SR, Drake AL, Heilig LF, Gaber M, McNely K, Schilling LM, Dellavalle RP. Statins, fibrates, and melanoma risk: a systematic review and meta-analysis. *J Natl Cancer Inst*. 2006 Nov 1;98(21):1538-46.
32. Dellavalle RP, Drake AL, Heilig LF, et al. Statins and fibrates for preventing melanoma. *Cochrane Database Syst Rev*. 2005 Oct 19;(4):CD003697.
33. Glynn SA, O'Sullivan D, Eustace AJ, Clynes M, O'Donovan N. The 3-hydroxy-3-methylglutaryl-coenzyme A reductase inhibitors, simvastatin, lovastatin and mevastatin inhibit proliferation and invasion of melanoma cells, *BMC Cancer*. 2008 Jan 16;8:9.
34. Koomen ER, Joosse A, Hering RM, Casparie MK, Bergman W, Nijsten T, Guchelaar HJ. Is statin use associated with a reduced incidence, a reduced Breslow thickness or delayed metastasis of melanoma of the skin. *Eur J Cancer*. 2007 Nov;43(17):2580-9.
35. Kuoppala J; Lamminpää A; Pukkala E. Statins and cancer: A systematic review and meta-analysis. *Eur J Cancer*. 2008; 44(15):2122-32 (ISSN: 1879-0852).
36. Dobritoiu A, Turcu G, Forsea D. Acute generalized exanthematous pustulosis induced by simvastatin, *Therapeutics, Pharmacology and Clinical Toxicology*, vol XIV, 4, 306-308.
37. Ali A, Martin JM. Hair growth in patients alopecia areata totalis after treatment with simvastatin and ezetimibe, *J Drugs Dermatol*, 2010 Jan;9(1):62-4.
38. Robins DN. Case reports: alopecia universalis: hair growth following initiation of simvastatin and ezetimibe therapy, *J Drugs Dermatol*, 2007 Sep;6(9):946-7.
39. AS Wierzbicki. Lipid-lowering drugs in lupus: an unexplored therapeutic intervention, *Lupus* (2001) 10, 233±236.
40. Farideh Jowkar, Mohammad Reza Namazi. Statins in dermatology, *International journal of dermatology*, 2010, 49, 1235-1243.