



## PIGMENTED PURPURIC DERMATITIS (CASE PRESENTATION)

N. Iagăru<sup>1,2</sup>, Monica Dărmănescu<sup>2</sup>, Irina Mărgăritescu<sup>3</sup>, D. Chirița<sup>3</sup>

<sup>1</sup> UMF "Carol Davila"

<sup>2</sup> The Institute of Mother and Child Care "Alfred Rusescu"

<sup>3</sup> MD, Domina Sana Medical Center

---

**Abstract.** The pigmented purpuric dermatoses are a group of chronic diseases of unknown etiology that have a distinctive clinical appearance. They are characterized by extravasation of erythrocytes in the skin with marked hemosiderin deposition. The pigmented purpuric dermatoses are infrequently reported in preadolescent children, except for the Schamberg disease that may occur in persons of any age. Usually, for all the pediatricians, purpura is a concerning sign of a possible systemic (infectious, hematologic-oncologic or immunologic) disease, especially in small children. We report a case of a 7 year-old male with progressive purpura who underwent extensive laboratory investigations to rule out a systemic disease. Based on the laboratory findings and clinical course, the diagnosis of purpuric pigmentary dermatitis (Schamberg's purpura) was established.

**Keywords:** Schamberg's purpura, children

---

### Background

The pigmented purpuric dermatoses are a group of chronic diseases of unknown etiology that have a distinctive clinical appearance. They are characterized by extravasation of erythrocytes in the skin with marked hemosiderin deposition. These clinical entities are histologically indistinguishable and, probably, represent a spectrum of the same disease. The purpuric dermatoses are infrequently reported in preadolescent children, except for the Schamberg disease that may occur in persons of any age.

### Objectives

Usually, for all the pediatricians, purpura is a concerning sign of a possible systemic (infectious, hematologic-oncologic or immunologic) disease, especially in small children. This is the reason for our case presentation.

### Case presentation

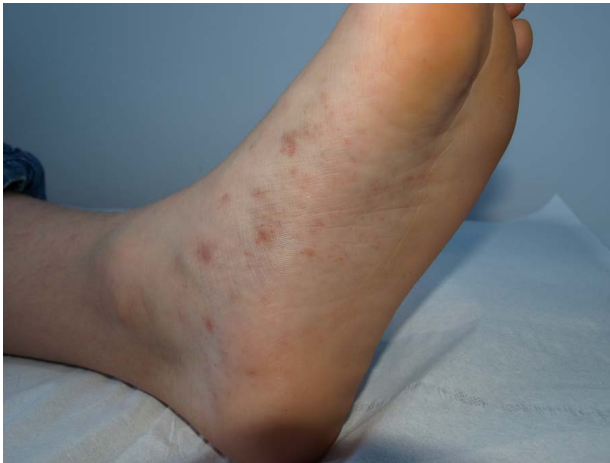A 7 year old male was admitted to our hospital for the first time with a peculiar red-brown-yellowish nonpalpable purpura on the hands and feet, including the palms and soles, but also on the knees and the upper lip. These lesions were not itching. The color of the teguments was yellow, carotenic, on his palms and soles. Other clinical signs: minor cervical adenopathy and a remarkable asymptomatic joint hypermobility. The onset was five months prior to admission with red maculae on the palms and soles (Fig.1, and Fig.2). After 3 weeks they extended on the dorsal aspects of the hands and feet and also on the knees, elbows and neck. All these areas became hyperpigmented over the following weeks, but the nonpalpable purpura and petechiae recurred. The patient was admitted to the Infectious Diseases Hospital for a month. Laboratory investigations (HIV, EBV, HBsAg, HCV, Herpes Virus 1 and 2, TPHA) were negative, except for IgM antibodies against *Borrelia burgdorferi* (28.96 u/ml; negative value < 20 u/ml). Some of the immunological investigations including ANA (1/160), anti-RNP (1/160), and anti-mitochondrial antibodies (1/160) were positive together with a

---

### Nicolae Iagăru

The Institute of Mother and Child Care "Alfred Rusescu", Bucharest

e-mail: iagarun@yahoo.com



**Figure 1.** Discrete and grouped petechiae and subtle purpuric papules forming poorly circumscribed red-brown patches on the feet and lower legs



**Figure 2.** Grouped petechiae on the dorsal aspects of the right hand

low serum complement fraction C3 of 38 mg/dL (normal values: 55-120 mg/dL). Serum immunoglobulins concentrations were normal. Circulating immune complexes: 64 IU (normal values: < 70). The patient received Ceftriaxone IV during the next 30 days, followed by azithromycin for 5 days. ESR was normal, but a remarkable transitory leukopenia (1690/cmm) with severe neutropenia was noted (13.2% = 223/cmm). At this stage of the disease the patient was transferred to our department of rheumatology. He appeared to be in a good state of nutrition with a weight of 22 kg and a height of 110 cm. The first clinical impression suggested Henoch-Schönlein purpura (HSP), but this was ruled out due to the six months of persistent non-palpable petechial purpura, without any signs of articular, abdominal or urinary involvement. Laboratory data reconfirmed normal CBC, acute phase reactants,

normal urinalysis and normal BUN. ELISA IgM antibodies against *Borrelia* were equivocal (21.40 u/ml), while IgG was negative. RF, anti-dsDNA, anti-Sm, anti-Ro, anti-La, c-ANCA and p-ANCA antibodies were negative. Serum complement fractions C3 and C4 were within normal limits. Tests for antiphospholipid syndrome (Ig anti-cardiolipin and lupus anticoagulant) were also negative.

Skin biopsy showed perivascular edema, numerous extravasated red blood cells, and small inflammatory perivascular mononuclear infiltrate, predominantly lymphocytic in the upper dermis (Fig.3A and 3B).

**Treatment:** Prednisone (1 mg/kg/day) and hydroxychloroquine (5 mg/kg/day). Over the following 5 months a slight improvement of the skin lesions was noted, but periodically, at every 2 weeks, they recurred. Also, every upper acute respiratory infection triggered new recrudescence of the hemorrhagic skin lesions. Thus, azathioprine (2.5 mg/Kg/day) was added to prednisone and hydroxychloroquine during the next 12 months. After 6 weeks of therapy no new lesions were noted, and the old lesions were replaced by brown pigmentation. The dose of prednisone was gradually tapered and withdrawn after 18 months. Also, hydroxychloroquine was stopped after 18 months of treatment. The patient is currently in remission without treatment in the last 18 months (now, he is 10 years-old, 3 years after the onset).

## Discussions

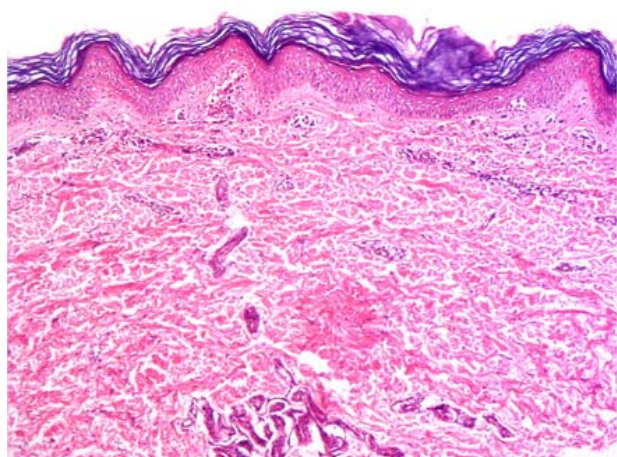
Pigmented purpuric dermatoses (synonyms: capillaritis, purpura progressiva pigmentosa) have been traditionally classified into 5 clinical entities [1,2]: **Schamberg's purpura** (typically presenting as „cayenne pepper“ spots on lower extremities, about half of cases); **Majocchi's purpura** (described as purpura annularis telangiectoides, about 5%); **lichen aureus** (characterized by a solitary golden-colored patch with purpura, about 10%); **Gougerot-Blum purpura** (typically presenting as lichenoid papules with purpura on lower extremities, about 5%); **eczematid-like purpura of Doucas and Kapetanakis** (characterized by itching and orange-colored pigmentation, about 10%). As their etiology is unknown, and no clear distinction has been established between different patterns other than on clinical morphological grounds, classification remains clinical [1,2].

**The etiology** of chronic pigmented purpuras is unknown. Many drugs and food additives, external contact agents, and infections were involved [2,3,4]. Also, systemic diseases or local conditions of the skin may lead to localized, mild purpura with hemosiderin deposition and secondary melanin pigmentation. However, venous hypertension, ex-

ercise, and gravitational dependency are important cofactors that appear to influence disease presentation. Identification of pigmented purpuric dermatoses secondary to a systemic cause is potentially important [1]. There are indications that immune mechanisms are involved. These include the deposition of immunoglobulins and/or complement around dermal vessels and modulation of cellular adhesion molecules in dermal endothelial cells and in lymphocytes in lesional skin [1,2]. Strong expression of endothelial cell adhesion receptors ICAM-1 and ELAM-1 may determine the pattern of the infiltrate [1]. The cellular infiltrate in all types contains CD4+ T cells in close contact with CD1a+ Langerhans cells, suggesting that a cell-mediated immune reaction is operative [1].

Infections, like haemolytic streptococci, toxoplasma and rickettsiae have been linked to development of pigmented purpuric dermatoses [1]. More recently, hepatitis viruses B and C were reported in association with pigmented purpuric dermatoses [4]. Although we did not find any prior reported case with this etiology, the positive IgM antibodies against *Borrelia burgdorferi* in our case may involve this infectious agent, although the parents denied a history of arthropod bite. However, they did not exclude the contact with an infected environment.

**Histologically** (Fig.3A and 3B), a perivascular T-cell lymphocytic infiltrate is centered on the superficial small blood vessels of the skin (capillaritis), without frank vasculitis, which show signs of endothelial cell swelling and narrowing of the lumen. Extravasation of red blood cells with marked hemosiderin deposition in macrophages is also found, but no fibrinoid necrosis of vessels [1,2,6].

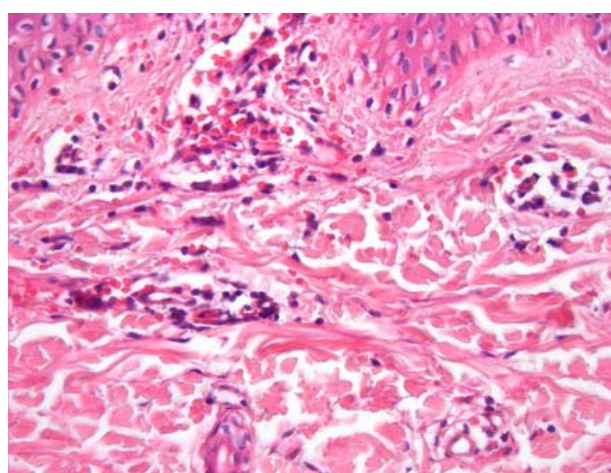


**Figure 3A.** Superficial perivascular dermatitis in an early lesion of persistent pigmented purpuric dermatitis (original magnification x100)

Typically, our case is asymptomatic, without systemic findings. The hallmark of a pigmented purpuric dermatosis is its characteristic orange-brown, speckled, cayenne pepper-like discoloration. The presence of chronic progressive pigmentary and hemorrhagic lesions on the lower limbs in a preadolescent child may be a proof to consider our case as Schamberg disease, the most common type and the most common present in children. Although Schamberg's purpura was initially described in 1901 in an 11-year-old boy, this entity is rarely described in preadolescent children and adolescents between 8 and 15 years of age. The largest series of preadolescent children before 10 years of age with Scamberg's purpura was reported by Torreló *et al* [2].

**Differential diagnosis:** thrombocytopenia (due to immunologic, oncologic or infectious diseases), vasculitis (Henoch-Schönlein Purpura) coagulopathy (due to hereditary or infectious diseases), drugs (NSAIDs, steroids), and traumatic purpura were excluded. We cannot explain the association of purpuric pigmentary dermatitis with carotenoderma, except maybe as an aleatory phenomenon.

**Treatment.** To date, no treatment has demonstrated a consistently beneficial effect. There is a little experience with topical steroids, pentoxifylline [7], griseofulvin, PUVA and antiallergic drugs [2]. The high degree of recurrence, the extension of chronic purpuric lesions and the presence of ANA, anti-RNP, and anti-mitochondrial antibodies, together with a low serum complement fraction C3 in the first five months after the disease's onset argued our apparently redundant treatment, but in view of the benign nature of the pigmented purpuras, the use of aggressive therapies in infants



**Figure 3B.** High magnification showing numerous extravasated erythrocytes in the upper part of the dermis and a sparse superficial perivascular infiltrate of lymphocytes (original magnification x400)

and children seems not to be justified [1].

**Prognostic.** The clinical course is chronic, with periods of improvement and worsening. We wait for new recurrences of the purpuric lesions in our patient, but for now he is in a very good condition.

## Conclusions

The purpuric pigmentary dermatitis is infrequently reported in preadolescent children, but when the pediatric practitioners meet it, a lot of differential diagnosis and treatment issues can appear. The presented case demonstrates this rare cause of purpura.

## References

1. A. Zvulunov, I Avinoach, Hatskelzon L, Halevy S. Pigmented purpuric dermatosis (Schamberg's purpura) in an infant. *Dermatology Online J* 1999;5(1):2.
2. Torrelo A, Requena C, Mediero GI, Zambrano A. Schamberg's purpura in children: A review of 13 cases. *J Am Acad Dermatol* 2003; 48, 1:31-33.
3. Darius Mehregan, Jennifer Michelle Hey. Pigmented Purpuric Dermatitis, *Dermatology Online J* Updated: Jan 19, 2010.
4. Yung A, Goulden V. Pigmented purpuric dermatosis (capillaritis) induced by bezafibrate. *J Am Acad Dermatol*, 53,1,2005:168-169.
5. Dessoukey MW, Abdel-Dayem H, Omar MF, Al-Suweidi NE. Pigmented purpuric dermatosis and hepatitis profile: a report of 10 patients. *Int J Dermatol* 2005;44:486-8.
6. Paller SA, Mancini JA. Pigmented purpuric eruptions (Vascular disorders of infancy and childhood) in *Hurwitz Clinical Pediatric Dermatology, Third Ed., Elsevier Saunders, 2006: 337-338.*
7. Kano T, Hirayama K, Orihara M, Shiohara T. Successful treatment of Schamberg's disease with pentoxifylline. *J Am Acad Dermatol* 1997;36:827-830.