



BLUNT ABDOMINAL TRAUMA: SEVERITY FACTORS IN HOLLOW VISCUS INJURIES

Ioana Iftimie-Năstase, M. Beuran

Department of General Surgery, Clinical Emergency Hospital, Bucharest

Abstract. Background. The purpose of this paper is that of assessing the prognostic factors of gravity for patients with blunt abdominal trauma and associated hollow viscus and mesentery injuries, as well as evaluating the efficiency of imaging methods as diagnostic tools in these cases. Patients and methods. This paper is a mixed cohort study, both retrospective and prospective, between 2004 and 2012, being currently underway. The patients included in the study are multiple trauma patients admitted in the ICU and surgical wards of the Clinical Emergency Hospital, Bucharest. The patients included in the study were victims of motor vehicle accidents, assaults, falls from height, etc. and their inclusion in this study relied on predetermined criteria. Conclusions. Hollow viscus injuries are the main concern in blunt abdominal trauma patients with associated visceral lesions, including those treated non-operatively, since clinical examination is notoriously unreliable in making a diagnosis in these cases and imagery tools may also provide equivocal results, leading to blank laparotomies or missed hollow viscus injuries, which in turn lead to an increased rate of complications: hemoperitoneum/peritonitis- MOFS-death.

Keywords: blunt abdominal trauma, hollow viscus injury

Introduction

Blunt hollow viscus injury (HVI) is an infrequent diagnosis in multiple trauma patients, its incidence hovering around 1% (0.7-8.5%)[1]; other authors indicated an incidence of bowel and mesenteric injuries in 5% of blunt abdominal trauma (BAT) patients, at laparotomy [2].

Unlike patients with penetrating injuries in whom HVI is more common and more easily detected, the patient with blunt abdominal trauma rarely presents with clinical evidence of a ruptured viscus [3]. Therefore, solid organ injuries and their direct consequence, hemodynamic instability, draw the attention much more quickly and present a higher priority in the emergency management of the BAT patient, leaving the HVI undiagnosed unless the clinical picture is highly suggestive [4,5,6].

The intestine is the third most commonly injured abdominal organ in blunt trauma [7], with the most common mechanism of injury including compression of the abdomen by a seat belt in motor vehicle accidents, a strong direct blow to the abdomen and falls from height [8].

The increasing use of computed tomography (CT) for diagnostic evaluation of the patient with blunt abdominal trauma and selective non-operative management of solid organ injuries have contributed to some of the difficulties and controversies in the management of hollow visceral injuries following blunt trauma [4].

The diagnosis of hollow viscera injury following blunt abdominal trauma is notoriously difficult to pinpoint to both the surgeon and the radiologist because of the lack of specific and reliable clinical and radiological findings. This is even more challenging during the first 4-6 hours from admission because the clinical picture is usually dominated by solid organ injuries, hemodynamic instability, equivocal clinical examination, missed lesions placing the patients with bowel trauma to an increased

Ioana Iftimie-Năstase

Clinical Emergency Hospital
8 Calea Floreasca, Bucharest, Romania
E-mail: dr_iftimienastaseioana@yahoo.com

risk for developing peritonitis and subsequent severe complications, including death [9].

An accurate history of the traumatic event can help determine the potential for intra-abdominal injuries. Three mechanisms by which blunt trauma can cause HVIs have been proposed. The first mechanism implies compressing/crushing of fluid/air filled bowel loops against the spinal column by a seat belt. This results in local lacerations to the bowel wall and mesentery, mural and mesenteric haematomas, transaction of the bowel, localised devascularisation and full thickness contusions [10].

The second mechanism would be rapid deceleration that causes a rupture of the bowel in the vicinity of fixed points (ligaments) and usually leads to perforations at a point situated between the freely mobile and the fixed portion of the bowel [8].

The third mechanism is a burst injury, that occurs when the intraluminal pressure exceeds the tensile strength of the bowel wall. Full-thickness perforations due to bursting forces occur more commonly in the small intestine [10].

Certain patterns of blunt abdominal injury should alert the clinician as to the probability of gastric and small bowel perforations. Physical examination reveals abdominal marks from compression by a seat belt or from a blow, while abdominal tenderness represents an unreliable clinical diagnostic sign [8].

A variety of diagnostic tests have been used to further evaluate the abdomen following blunt and penetrating injuries. Diagnostic peritoneal lavage (DPL) is very sensitive in detecting intra-peritoneal injury but is now infrequently used. The most common peritoneal lavage finding with bowel injuries is gross blood [11]. However, this may be due to associated solid organ or mesenteric injuries.

Peritoneal lavage with blood cell count has been used to diagnose hollow viscus injury. However, Jacobs et al. found that a lavage white blood cell count $>500/\text{mm}^3$ as the sole positive lavage criteria to be a nonspecific indicator of intestinal perforation [12]. It was suggested that sequential determinations of DPL and WBC may be useful in the diagnosis of intestinal perforation.

Morphologic changes of the small bowel identified by ultrasound are suggestive of diagnostic delay. The US can also reveal free fluid, mandating a further thorough evaluation, having a sensitivity of 81.3% and a specificity of 100% [13]. Radiologic evaluation for pneumoperitoneum is not reliable, not even in the cases of intestinal perforation [8].

Although it has a high rate of false-negative results, the CT scan is the most commonly used diagnostic modality in evaluating the abdomen in hemodynamically stable blunt trauma victims [7].

Findings suspicious of blunt bowel/mesenteric

injuries on CT include unexplained intra-peritoneal fluid, pneumoperitoneum, bowel wall thickening, mesenteric fat streaking, mesenteric hematoma, and extravasation of either luminal or vascular contrast [14], CT scans having a sensitivity of 82% and a specificity of 75% [15], with up to an overall 34% false-negative results [2,16], although results differ, with wide variations.

Direct diagnostic signs include: contrast extravasation \pm pneumoperitoneum (fig.1 and fig. 2).

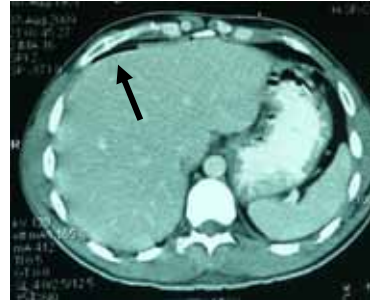


Figure 1. Pneumoperitoneum

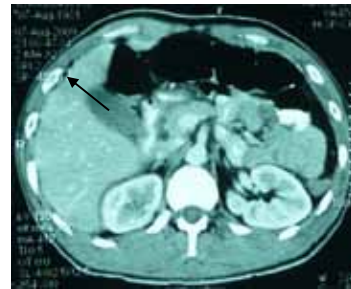


Figure 2. Minimal pneumoperitoneum

Indirect diagnostic signs include: bowel wall thickening, mesenteric hematoma and free fluid in the absence of solid organ injury.

In hemodynamically stable patients, exploratory laparoscopy is a suitable diagnostic tool, allowing the surgeon to identify and possibly repair the injury, in addition to a thorough examination of the entire abdominal cavity [6].

Materials and methods

Between 2004 and 2009, there were 287 blunt abdominal trauma patients admitted to the ICU/Surgical ward and operated on. Over 50% of the patients were involved in motor vehicle accidents and over 100 of them exhibited hollow visceral injuries and/or mesentery injuries.

Data, including age, gender, the mechanism of injury (multiple trauma patients with blunt abdominal trauma or simple BAT), the presence of

shock at admission (systolic BP<90 mmHg and a HR>100 bpm), initial Glasgow Coma Scale (GCS), Injury Severity Score (ISS), time from admission to operation, associated abdominal injuries, other associated injuries, length of total hospital stay, were recorded and entered into a computerized database, for statistical analysis.

One of the goals of the present study was to assess the role of different modalities in the diagnosis of hollow viscus injury and the decision for laparotomy. To determine if a delay in operative intervention was a risk factor for mortality, the time from injury to laparotomy was compared between those who survived and those who died. An attempt was made to establish the reasons for delay between the time of injury and the time of laparotomy in excess of 6 hrs.

Major associated injuries of the head, face, solid abdominal viscera, thorax, pelvis, axial skeleton, major blood vessels and long bones were also recorded [10]. Injuries to the abdominal organs were classified as major if AIS (Abbreviated injury Score) grade was 3 or more.

The indications for laparotomy were categorized as one of the following: hemodynamic instability with reasonable clinical suspicion of an intra-abdominal cause, diagnostic CT scan, positive diagnostic peritoneal lavage, positive abdominal signs or positive contrast study.

Results and discussion

In contrast to penetrating abdominal trauma, which produces intestinal injuries in as many as 90% of cases, blunt abdominal trauma is associated with a considerably lower incidence of bowel injuries (3-18%)[8].

Although it may be expected that patients sustaining perforation of hollow viscus, particularly of the small bowel, exhibit evidence of peritoneal irritation after blunt abdominal trauma, allowing an early and prompt diagnosis, reports suggest that such injuries actually tend to be diagnosed late because of the subtlety of clinical signs and the difficulty of their interpretation [8].

Since, usually, there are no reliable initial clinical signs of intestinal injury, the diagnosis is mainly an intuitive process suggested by the mechanism of injury, physical findings, followed by a thorough US examination and/or CT scan.

Three mechanisms of injury by which blunt trauma causes injury to the bowel and mesentery have been proposed in the early 1920s by Vance [10, 19]. A first mechanism would presume compressing/crushing of an air/fluid filled hollow viscus between an object, such as the seat belt, and the rigid skeleton, posteriorly. This results in local lacerations to the bowel wall and mesentery,

mural and mesenteric haematomas, transection of the bowel, localised devascularisation and full thickness contusions [10].

The second mechanism of injury is rapid deceleration, thus creating shearing forces between the relatively fixed and mobile segments of the intestine [10].

The third mechanism of injury is represented by burst type injuries caused by sudden increase in intraluminal pressure exceeding the tensile strength of the bowel wall [10].

Patients with a significant history of blunt abdominal trauma and minimal clinical signs should be observed closely, with serial clinical examinations being performed on a regular basis. This helps especially in patients with additional associated intra-abdominal injuries [8,10].

Physical examination may be unspecific and unreliable especially in unconscious or intubated patients. A bruise across the abdomen inflicted by a seat belt ("seat belt sign") and ongoing abdominal pain are known associated risk factors for HVI, particularly SBI [8].

In our study, 57% of patients had had equivocal clinical examination and 40% had had obvious signs of peritoneal irritation.

Ultrasound examination may yield some indirect signs, such as free peritoneal fluid, which can also arise from solid organ injury and is therefore an unequivocal sign of intestinal injury. On the other hand, the absence of free peritoneal fluid does not necessarily exclude HVI [8].

In our study, US was positive in almost 70% of patients, having been performed in 104 cases.

DPL was performed in 3 patients and was positive in 1 case.

Out of 45 patients who had had abdominal x-rays performed, only 5 (11%) displayed pneumoperitoneum.

We performed a CT examination in 64 patients, with positive results of HVI in 61 cases (96%). 58 scans displayed direct diagnostic signs that led to a HVI diagnosis and 3 showed indirect signs.

Although HVIs are rarely immediately life-threatening, their significance lies in the high association of delayed morbidity and mortality from intra-abdominal sepsis arising when such injuries are missed [18].

7% of the patients included in this study were diagnosed and operated on with a minimum of 24 hour delay and 81% were diagnosed and operated in less than 6 hours.

Delay in diagnosis may be fatal, yet unnecessary laparotomies should be avoided and, in the case of solid organ injuries, priority should be given to conservative management whenever possible [8]. However, Fang et al. observed that a delay in surgery

of more than 24 hours after the injury in patients with perforated SBI did not significantly increase mortality, but was associated with a dramatic increase in the incidence of complications [19].

Morbidity and mortality in patients with intestinal trauma depends on concomitant injuries, the mortality rates being considerably lower for patients with isolated intestinal lesions [8] (16% in our study) compared to patients sustaining additional intra-abdominal injuries (34%).

We estimated an overall mortality rate of approximately 25%, given the fact that the study is still under way.

Over 30% of the recorded deaths had presented at least one hollow viscus injury and over 60% of these were accompanied by other severe injuries, mainly head trauma and pelvis injuries.

The highest mortality rates were noticed in patients with gastric (over 60% of patients), duodenal and colonic injuries (40% of cases).

Since, usually, there are no reliable initial clinical signs of intestinal injury, the diagnosis is mainly an intuitive process suggested by the mechanism of injury, physical findings, followed by a thorough US examination and/or CT scan.

Undiagnosed HVIs pose a serious challenge since the complications that arise can be severe, potentially lethal.

Conclusions

Hollow viscous injuries are the main concern in blunt abdominal trauma patients with associated visceral lesions, including those treated non-operatively, since clinical examination is notoriously unreliable in making a diagnosis in these cases and imagistic tools may also provide equivocal results, leading to blank laparotomies or missed hollow viscus injuries, which in turn lead to an increased rate of complications: hemoperitoneum/ peritonitis-MOFS-death.

ACKNOWLEDGEMENT: „This paper is supported by the Sectoral Operational Programme Human Programme Human Resources Development (SOP HRD), financed from the European Social Fund and by the Romanian Government under the contract number POSDRU/6/1.5/S/S17”

References

1. Campillo-Soto A, Soria-Aledo V, Renedo-Villarroya A, Millán MJ, Flores-Pastor B, Girela-Baena E, et al. Computerised tomography in the diagnosis of intestinal and mesenteric injuries in closed abdominal trauma, *Cir Esp*, 2009 Jul;86(1):13-6. Epub 2009 Jun 13.
2. Brofman N, Atri M, Hanson JM, Grinblat L, Chughtai T, Brennenman E. Evaluation of bowel and mesenteric blunt trauma with multidetector CT, *Radiographics*, 2006 Jul-Aug;26(4):1119-31.

3. Brownstein MR, Bunting T, Meyer AA, et al. Diagnosis and management of blunt small bowel injury: A survey of the membership of the American Association for the Surgery of Trauma. *J Trauma*, 2000;48:402.
4. Butela ST, Federle MP, Chang PJ, Thaete FL, Peterson MS, Dorvault CJ, et al. Performance of CT in detection of bowel injury, *Am J Roentgenol*, 2001 Jan;176(1):129-35.
5. Fakhry SM, Brownstein M, Watts DD, et al. Relatively short diagnostic delays (<8 hours) produce morbidity and mortality in blunt small bowel injury: an analysis of time to operative intervention in 198 patients from a multicenter experience, *J Trauma*. 2000 Mar;48(3):408-14.
6. Nicolau AE, Ionescu G, Mehnic et al. Laparoscopy in abdominal trauma. Preliminary report in 37 cases, *Chirurgia (Bucur)*, 2001 Nov-Dec;96(6):563-72.
7. Fakhry S, Watts D, Daley B, et al. Current diagnostic approaches lack sensitivity in the diagnosis of perforating blunt small bowel injury (SBI): Findings from a large multi-institutional trial. *J Trauma*, 2001 51:1232, (abstract).
8. Vidmar D, Pleskovic A, Tonin M. Diagnosis of Bowel Injuries from Blunt Abdominal Trauma. Our Experience, *European Journal of Trauma*, Volume 29, Number 4, 2003, 220-227.
9. Diebel LN. Section III - Management of Specific Injuries > Chapter 34 - Stomach and Small Bowel, Feliciano DV, Mattox KL, Moore EE- Trauma, 6th ed , USA, McGraw-Hill, 2008, pag 682-698.
10. Hughes TMD, Elton C, Hitos, Perez JV, McDougall PA. Intra-abdominal gastrointestinal tract injuries following blunt trauma: the experience of an Australian trauma centre, *Injury, Int. J. Care Injured*, 2002, Volume 33, Issue 7, Pages 617-626.
11. Malhotra AK, Ivatury RR, Latifi R. Blunt abdominal trauma: evaluation and indications for laparotomy, *Scand J Surg*, 2002;91(1):52-7.
12. Jacobs DG, Angus L, Rodriguez A, et al. Peritoneal lavage white count: A reassessment. *J Trauma*, 1990, 30:607.
13. Brody JM, Leighton DB, Murphy BL, Abbott GE, Vaccaro JP, Jagminas L et al. CT of blunt trauma bowel and mesenteric injury: typical findings and pitfalls in diagnosis, *Radiographics*, 2000, Nov-Dec;20(6):1525-36.
14. Peters E, LoSasso B, Foley J, Rodarte A, Duthie S, Senac MO. Blunt bowel and mesenteric injuries in children: Do non-specific computed tomography findings reliably identify these injuries? *Pediatric Critical Care Medicine*, November 2006, Volume 7, Issue 6 pp 551-556.
15. Rey Valcárcel C, Turégano Fuentes E, Carlin Gatica J, Ruiz de la Hermosa A, Vásquez Jiménez W, Pérez Díaz D et al. Gastrointestinal and mesenteric injuries in the trauma patient: incidence, diagnosis delay and prognosis, *Cir Esp*, 2009 Jul;86(1):17-23. Epub 2009 May 28.
16. Smith ZA, Postma N, Wood D. FAST scanning in the developing world emergency department, *S Afr Med J*, 2010 Jan 29;100(2):105-8.
17. Hackam DJ, Ali J, Jastaniah SS. Effects of other intra-abdominal injuries on the diagnosis, management, and outcome of small bowel trauma, *J Trauma*, 2000 Oct;49(4):606-10.
18. Vance BM. Traumatic lesions of the intestine caused by non-penetrating blunt force. *Arch Surg* 1923; 7; 197-212.
19. Fang JF, Chen RJ, Lin BC, Hsu YB, Kao JL, Kao YC, Chen MF. Small bowel perforation: is urgent surgery necessary?, *J Trauma*. 1999 Sep;47(3):515-20.