



## DIAGNOSING AND TREATING THE FUNCTIONAL PROBLEMS OF THE PATIENT WITH UPPER SINGLE DENTURE - CASE REPORT

Oana-Cella Andrei<sup>1</sup>, Ioana Radu<sup>2</sup>

<sup>1</sup> Lecturer, PhD, Department of Mobile Prosthetics, Faculty of Dentistry, University of Medicine and Pharmacy „Carol Davila” Bucharest

<sup>2</sup> PhD student, Department of Mobile Prosthetics, Faculty of Dentistry, University of Medicine and Pharmacy „Carol Davila” Bucharest

---

**Abstract.** The edentulous state of the oral cavity is equivalent to the absence of any other body part with specific morphological and psychological sequelae. This case presents a patient with an edentulous maxillary arch opposing a dentate mandibular arch. The dentist has a difficult mission in evaluating the biomechanical differences in the supporting tissues for the two arches and applying the appropriate procedures to produce and maintain the conditions necessary for long-term treatment success. The dental literature evidences suggest that the maxillary arch exhibits earlier tooth loss due to various factors and that the mandibular anterior teeth are preserved the longest, so this case focuses on the oral condition in which the maxillary arch is edentulous and opposed by a natural and partial restored mandibular dentition. The main problem is that there are important qualitative and quantitative differences between natural tooth and complete denture support: the natural dentition is capable of specialized responses to occlusal demands that preserve its function, whereas mucoperiosteal bone is not and it will respond in a variable way depending on age, sex and racial category. Therefore, the replacement of the missing maxillary dentition must provide an optimum distribution of the occlusal forces in order to minimize the negative effects in the compromised edentulous arch.

**Keywords:** single denture, stability, retention, occlusal plane, flabby ridge, bone resorption, vertical dimension of occlusion

---

### Introduction

The dental treatment's long-term goal in prosthodontics is to preserve the remaining structures. This goal is impossible to achieve without understanding the occlusal biomechanics that allows us to obtain a physiological occlusion: acceptable interocclusal distance, stable jaw relationship with bilateral tooth contacts in retruded closure, stable tooth quadrant relationships with axially directed forces, multidirectional freedom of

tooth contact throughout a small range (within 2 mm) of mandibular movements [1]. Unfortunately, when only one arch is edentulous, tooth position in the dentate arch may preclude such objectives being reached and the unfavorable force distribution may cause adverse tissue changes that are going to compromise optimum function. It is therefore critical to identify these problems and to correct them as soon as possible: arch relationship or occlusal plane discrepancies, jaw relationship extremes, excessively displaceable denture-bearing tissue.

Because of the presence of longstanding uncontrolled occlusal forces, important changes in the denture foundation can occur, as the accelerated loss of the bone [2] and the excessively displaceable tissue that come with the problem of the differential support capability to the same load. The forces of

---

**Oana-Cella Andrei**  
UMF "Carol Davila"  
19 Calea Plevnei Str., Bucharest  
email: cella.andrei@gmail.com

occlusion are resisted by the mucoperiosteum which allows some movement of the denture base by its resiliency. If the tissue changes allow excessive displacement, the movement of the denture under load will be greater with resultant dislodgement.

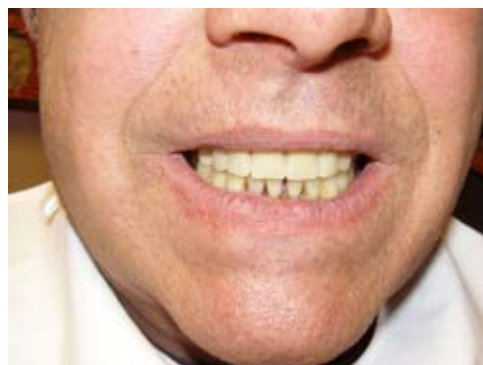The opposing arch's condition of an irregular occlusal plane also predisposes the denture to dislodgement. After the loss of the maxillary teeth and in the absence of the prosthetic treatment, the opposing dentition tends to tilt and extrude compared to a normal relationship which results in an unfavorable force distribution. The teeth that are most prominent in the vertical plane will be the subject of the selective grinding in order to ensure that a sufficient number of teeth will be in contact with the artificial ones in the same time[3].

Because of the pressures exerted by the mandibular remaining teeth, the alveolar maxillary ridge is extremely resilient and mobile (flabby ridge) due to the replacement of the bone by fibrous tissue. This is a consequence of the excessive load of the edentulous ridge and of the unstable occlusal conditions. This ridge will provide poor support for the future complete denture, but it may still provide some retention due to its resilient state.

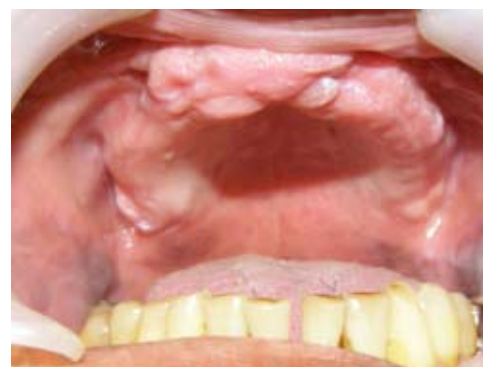### Case report

A 62 year-old male patient came to the office asking for the replacement of the upper complete denture repeatedly fractured. We made a complete case history and a careful oral examination. He told us he tried to replace the old denture two months ago, but he could not wear the new denture he was delivered because it was „too big and unstable”. He used his old complete denture instead, but it was again fractured. Finally, he came to our clinic to make a new prosthesis. The main complaints were: the fracture of the old denture, the poor stability and retention and the exaggerated dimensions of his second denture (figure 1).

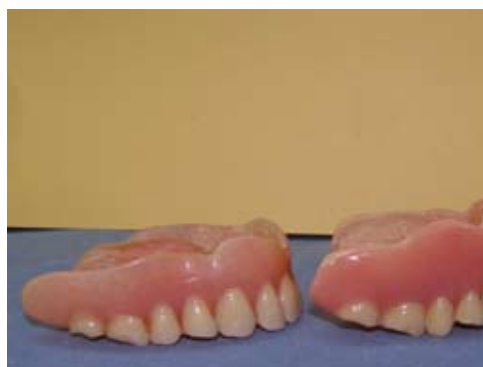The clinical and radiological exam revealed a total edentulous maxilla opposing a class III Kennedy mandible. The maxillary ridge appeared irregular, resilient and fibrous with two old decubitus lesions situated retrotuberositary. The mandibular teeth were malposed, tipped and super erupted and as a result the occlusion was far from harmonious and balanced (figure 2). The occlusal plane of both (first and second) dentures was uneven and as a result the unfavorable occlusal relationships tended to displace the maxillary denture causing soreness, mucosal



**Figure 1.** The facial aspect of the patient wearing the second denture shows an exaggerated vertical dimension of occlusion



**Figure 2.** The facial aspect of the patient wearing the second denture shows an exaggerated vertical dimension of occlusion



**Figure 3.** Both dentures are made without modifying the mandibular teeth with major consequences for the stability and retention

changes and ridge resorption[2]. The second denture was made at an exaggerated vertical dimension of occlusion and appeared big and uncomfortable so the patient was unable to wear it. On a daily basis he used his oldest denture that was repeatedly repaired after fracture [4] (figure 3).

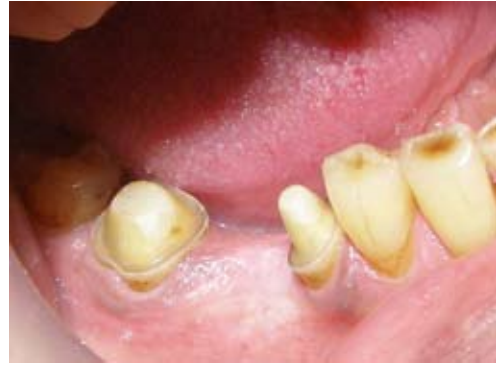The occlusal plane of the natural teeth was not parallel to the mean foundational plane of the

previous denture and this resulted in forces that tended to dislodge the denture rather than having a stabilizing effect on the application of occlusal forces. The placement of the artificial teeth was not on the center of the residual ridge and so they induced torquing and dislodging forces on the old denture during function. We also noticed signs of chronic irritation, hypertrophy and marked resorption on the upper jaw.

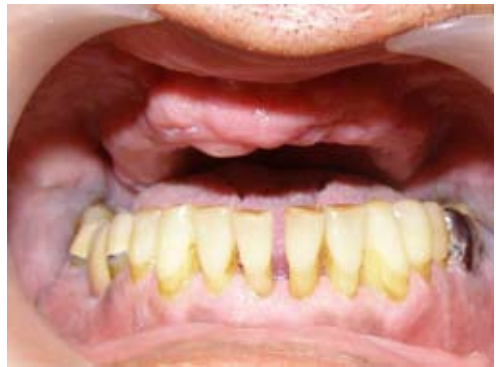We planed an accurate analysis of the remaining teeth in order to evaluate the forces they exert on the denture during function. We made the impressions for the diagnosis casts and mounted them in the articulator in order to evaluate the existing interarch space and the occlusal plane and to establish the modifications that had to be made on the natural teeth. We formulated a treatment plan and explained it to the patient who understood it and agreed to follow the necessary steps. After obtaining his consent to the treatment in writing, we started the operative procedures.

We evaluated the character of the occlusal plane on the lower study cast. We modified the study cast to correct the occlusal discrepancies and used it as a guide to duplicate these modifications in the mouth. In the absence of tooth 46, the patient used most of the time the left part of the mouth for chewing and this created more instability for the upper denture, more susceptibility to fracture and more resorption for the ridge on this side. We decided to restore the edentulous space of 46 with a porcelain-fused-to-metal bridge (figure 4). We planned the necessary adjustments for the mandibular teeth on the cast using a metal template as a guide [5]. When maximum contacts were evidenced between the study cast and the template, the procedure was duplicated in the mouth [6] and the natural teeth were reshaped by selective grinding (figure 5). To obtain stability during function, the denture teeth should not make contact on an inclined plane. After each modification of the occlusal plane, we added self-curing white acrylic resin on the artificial teeth of the old denture in order to restore the occlusion (figure 6). The total amount of the occlusal grinding that was required did not result in enamel penetration and we did not increase the faciolingual width of the natural teeth. In every next appointment, the patient mentioned the increasing stability of the old denture (used as interim prosthesis) during function.

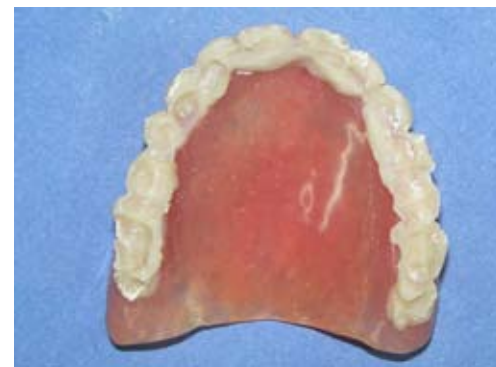The preliminary impression of the maxillary arch was taken (using a medium viscosity C-silicone ma-



**Figure 4.** The abutment teeth of the porcelain-fused-to-metal bridge used to restore the absence of 46



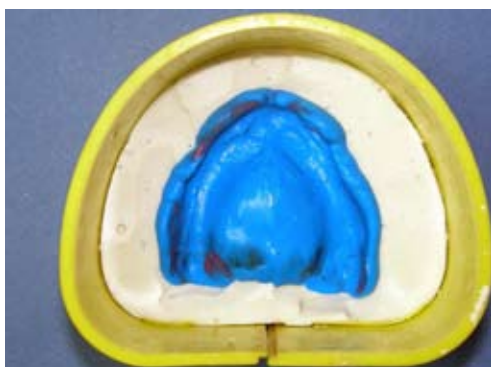
**Figure 5.** The maxilla is smaller than the mandible



**Figure 6.** Adding self-curing white acrylic resin on the old denture used as interim prosthesis

terial and the old denture as a tray) and checked for proper extension and coverage. The individual tray was made from light-curing resin and subjected to the dislodgement tests prior to taking the secondary impression. The posterior palatal seal was obtained using Kerr green stick compound and the margins were functionalized using GC Isofunctional. Selective relief was accomplished on the cast and within the tray relative to the clinical needs presented by the patient.

The second impression was taken using a medium viscosity vinyl polysiloxane and an open-mouth technique; after the setting of the material, the impression was boxed to preserve its details (figure 7). The dental technician fabricated an occlusion rim on the maxillary cast. We established the vertical dimension of occlusion using the conventional methods. On the rim we established bilateral and tripod stable centric stops and we recorded the centric relation. We verified that the occlusal plane is located in the middle of the interarch space to prevent the leverage effect onto the upper denture.

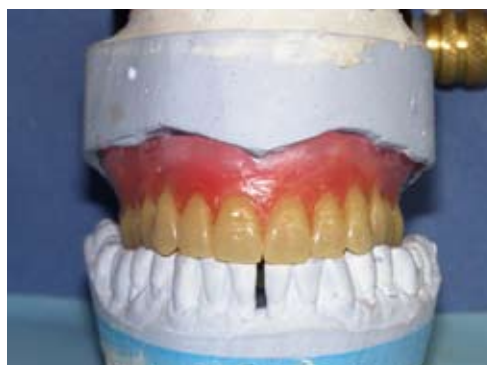

**Figure 7.** The second impression after the boxing phase was finished

We arranged the acrylic artificial teeth with the proper inclination and vertical overlaps following the corrected occlusal plane of the opposing natural teeth. For aesthetic reasons, on the anterior area we placed the teeth in approximately the position that they were in the patient's natural dentition, in a discreet vertical overbite. We used a shallow incisal guidance to minimize the stress on the anterior teeth and to increase the stability of the denture. For stability reasons on the posterior areas we mounted the artificial teeth in a reverse horizontal overlap or crossbite arrangement. The maxillary artificial teeth were arranged to obtain simultaneous multiple bilateral contacts and the best possible occlusal balancing contacts (figure 8). The central fossae of the maxillary artificial teeth were articulated with the lingual cusps of the mandibular teeth, thereby centralizing the occlusal contacts.


We considered that acrylic resin teeth are the first choice since they cause no wearing of the opposing natural teeth and they are the easiest to equilibrate. Their selection was determined by the character, size, shape and color of the existing natural teeth. The major disadvantage of the acrylic

resin teeth is their wearing, which in time results in a loss of vertical dimension of occlusion, but this is always preferable facing the resorption of the alveolar ridge because we can always make a new denture.



**Figure 8.** The trial denture and the arrangement of the artificial teeth in the new occlusal scheme

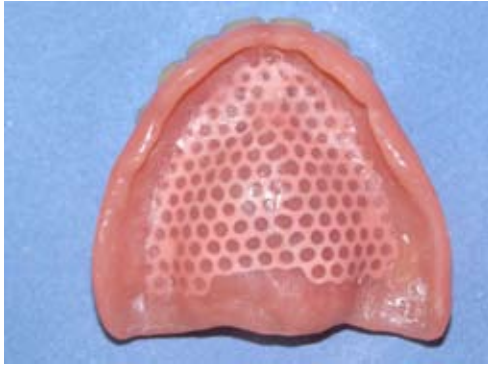
After the trial denture appointment, the technician made from perforated wax (figure 9) a casted metal reinforcement to prevent any future fracture of the acrylic base of the denture [7]. On this reinforcement he applied a pink opaque agent to obtain a better aesthetic effect avoiding the visibility of the grey color of the metal through the translucency of the base. The reinforcement was included in the wax base and the denture was waxed up, processed, polished and finalized in the dental laboratory (figure 10).



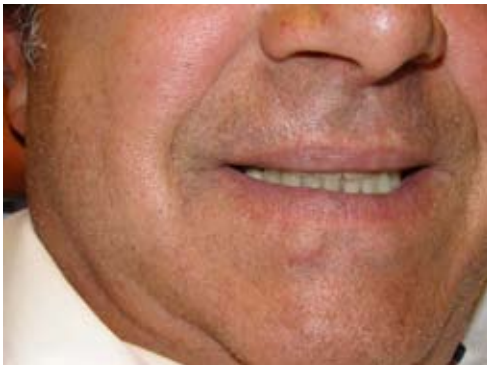**Figure 9.** The reinforcement of the denture prepared for casting

In the delivery appointment we evaluated the stability, the retention, the aesthetics, the phonetics and the base of the denture. One good sign was that the patient spoke clearly with the new denture from the very beginning. We checked the vertical dimension and the centric occlusion. When the oc-

clusal markings in centric relation were distributed equally in intensity and number, the occlusion was refined by grinding the teeth in order to ensure that there were no interferences and prematurities. The facial aspect was normal and the patient liked his new appearance (figure 11). He had no problem to adapt to the new complete denture and no adjustments were necessary for the acrylic base [8].



**Figure 10.** The aspect of the new denture



**Figure 11.** The facial aspect of the patient showing no signs of abnormalities

## Discussions

The case chosen for this article describes a common pattern of tooth loss which involves the completely edentulous maxillary area opposing a mandibular complement of natural teeth with missing first molars. In these situations, the remaining molars are often severely inclined mesially and their distal halves are supererupted. If this clinical situation is not corrected, the contact on the distal half of the lower molar produces the dislodging of the maxillary denture during functional movements. In the denture foundation, changes occur because of longstanding uncontrolled occlusal forces. Unfa-

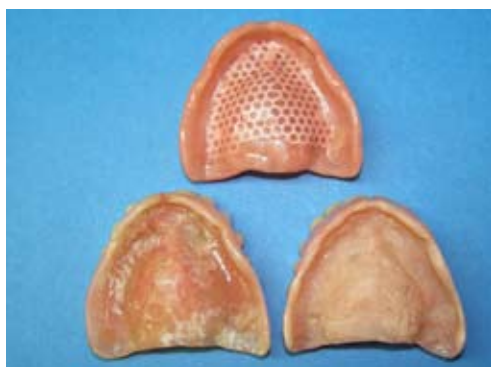vorable force distribution can cause adverse tissue changes that compromise optimum function. It is important to identify and to correct these changes. The teeth extraction result in a smaller maxilla compared to the dentulous state. The horizontal discrepancy between the arches anteriorly and posteriorly [9] make it difficult to direct occlusal forces to the denture bearing surface because the support is at distance from the denture tooth position. The best solution to correct this discrepancy is to place the posterior teeth in a reverse horizontal overlap or crossbite arrangement. For esthetic reasons this solution is not available in the anterior area because of the aesthetic impact on the maxillary lip of such a tooth position.

There are a lot of problems associated with the construction of a single denture designed to articulate and to function with a previously existing natural occlusal scheme, far more complex than those encountered with a complete edentulous patient. The treatment plan and the prognosis differ in these apparently similar clinical situations. The natural teeth are not aligned, shaped and positioned for good functional balance. When a denture is constructed opposing natural teeth, the placement of the artificial teeth in the most desirable location is prevented by their presence, since the artificial teeth have to occlude to their existing counterparts; this fact will create biomechanical and functional disadvantages. Then, the most important factor that should be evaluated prior to the initiation of treatment is the location of the occlusal plane in relation to the opposing supporting structures. The occlusal plane should be located in the middle of the interarch space (to prevent the leverage effect onto the upper denture) and it should be parallel to the mean foundational plane of the opposing edentulous ridge (to avoid the dislodging of the complete denture). The placement of the artificial teeth must be on the center of the residual ridge to increase the stability of the denture during function. The occlusal plane should have only a gentle curvature faciolingually and mediolaterally. It is then obvious that the alterations in the existing occlusal scheme are always necessary prior to the construction of a single complete denture. A lot of dentists are not taking into account the importance of modifying the occlusal plane, offering to the patient dentures that are permanently dislodged by their existing teeth and causing serious problems for the supporting mucoperiosteum structures on the long term because of the tissue changes.

The excessive displaceable tissue poses the problem of the differential support capability to the same load. The forces of occlusion are resisted by the mucoperiosteum which allows some movement of the denture base by virtue of its resiliency. When this displacement is excessive due to the tissue changes, the movement of the prosthesis under load is greater, with resultant dislodgement.

## Conclusions

The upper single denture can be functionally successful because of a large denture-bearing area offering stability. The single denture wearer is usually younger and therefore more adaptable than the totally edentulous patient. The tongue can develop habits for even more added stability. If the denture is made following the correct prosthodontic principles



**Figure 12.** A comparison between all the three dentures made for the same patient

and the patient offers a good collaboration [10], the long term success of the treatment is achieved<sup>11</sup>.

The single denture treatment requires the same chair time as that needed for the construction of two complete dentures and it is more demanding for both the dentist and the dental technician. The coordination to the occlusal surfaces is extremely difficult because of the inability to dictate the occlusal scheme<sup>12</sup>. In this case, without restoring the edentulous space of tooth 46 with a bridge and the selective grinding of the remaining mandibular teeth we could not obtain stability and retention

for the upper denture.

The most visible adverse sequelae of single denture treatment are the wearing of the natural teeth and denture fracture. Both are prevented in this case, the first one by using acrylic artificial teeth and the second one by using a casted metal reinforcement.

Finally, we planned and fabricated a complete maxillary denture that provided comfort, function, stability, retention and aesthetics. The patient was very happy with the new denture, and he could make the comparison with the other two dentures he had been offered before (figure 12).

## References

1. Zarb GA, Bolender CL et al. *Prosthodontic Treatment for Edentulous Patient twelfth ed.*, Mosby 2004:427-437.
2. Kalk W, Schwencke BM, Droulias N, ten Dam KM. *Treatment planning in patients with a severe reduced dentition*, *Ned Tijdschr Tandhelkd* nov 2009; 116(11):599-604.
3. Winkler S et al. *Essentials of Complete Denture Prosthodontics*, second ed., Ishiyaku EuroAmericca Inc. U.S.A. 2000:417-427.
4. Schneider RL. *Diagnosing functional complete denture fractures*, *J Prosthet Dent*, 1985; 54: 809-814.
5. Yurkstass AA. *Single dentures*, in Sharry JJ (ed): *Complete Denture Prosthodontics*, ed.2. New York, McGraw-Hill, 1968: 300
6. Tan HK. *A preparation guide for modifying the mandibular teeth before making a maxillary single complete denture*, *J Prosthet Dent* mar 1997; 77(3):321-2.
7. Farmer JB. *Preventive Prosthodontics: Maxillary denture fracture*, *J Prosthet Dent* 1983; 50:172-175.
8. Koper A. *The maxillary complete denture opposing natural teeth: problems and some solutions*, *J Prosthet Dent* 1987; 57:704-707.
9. Huang CC, Feng HL. *Analysis of the difference in the tissue surfaces between the old and new upper complete dentures*, *Zhonghua Kou Qiang Yi Xue Za Zi* apr 2009; 44(4):232-5.
10. Critchlow SB, Ellis JS. *Prognostic indications for conventional complete denture therapy: a review of the literature*, *J Dent* jan 2010; 38(1):2-9.
11. Zini A, Pietrokovski Y, Pietrokovski J. *The importance of correct diagnosis in complete dentures treatment*, *Refuat Hapeh Vehashinayim*, jul 2009; 26(3):15-9,69.
12. Driscoll CE, Masri RM. *Single maxillary complete denture*, *Dent Clin North Am* jul 2004; 48(3):567-83.