



## IDIOPATHIC HETEROTOPIC OSSIFICATION IN SOFT TISSUES AROUND ANKLE JOINT – CASE REPORT

C. Socoliuc<sup>1</sup>, Sabina Zurac<sup>1,2</sup>, Gianina Micu<sup>1</sup>, Cristiana Popp<sup>1</sup>, Luciana Nichita<sup>2</sup>,  
Adina Ene<sup>1</sup>, Alina Slavnea<sup>1</sup>, Florica Stăniceanu<sup>1,2</sup>, R. Fundulea<sup>3</sup>

<sup>1</sup> Colentina University Hospital, Department of Pathology

<sup>2</sup> “Carol Davila” University of Medicine and Pharmacy,

<sup>3</sup> Colentina University Hospital, Department of Orthopedics  
Bucharest, Romania

---

**Abstract.** Acute pneumonia was and still is one of the most important causes of morbidity and mortality. A patient with typical CAP presents sudden onset with chill, fever, pleural pain, cough, expectoration, dyspnea. Elderly patients may present an atypical clinical presentation: confusion, decompensation of underlying diseases. Chest radiography is recommended to patients suspected of having CAP. It is important to perform a severity assessment of CAP in order to decide whether to treat the patient with CAP as outpatient or as inpatient, in the ward or in the ICU. A lot of patients with CAP could be correctly treated with oral antimicrobial drugs.

**Keywords:** community-acquired pneumonia (CAP), etiology, susceptibility, resistance, severity, hospitalization

---

### Introduction

Heterotopic ossification (HO) represents the formation of mature, lamellar bone within soft tissues, usually after an initiating traumatic event [11]. This disease is etiologically and pathogenically related to myositis ossificans, a disease with mature bone formation within skeletal muscles with characteristic histopathology aspects. Although some authors consider the two conditions to be synonyms [6], HO comprises a wider anatomic distribution of lesions. It may occur in skin, subcutaneous tissue, skeletal muscle and periarticular tissue [5]. HO in soft tissue around joints usually presents as a rapid growing mass with acute, arthritis-like [7], inflammatory signs and symptoms. These clinical aspects can raise the suspicion of a malignant tumor.

---

#### Dr. Claudiu Socoliuc

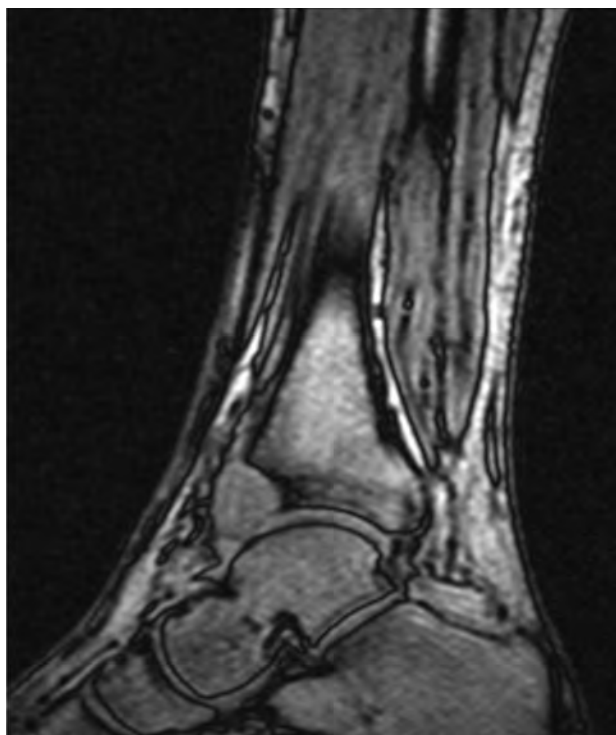Colentina University Hospital  
21 Stefan cel Mare Str.  
cod 020125 Bucharest, Romania  
e-mail: socoliucc@yahoo.com

### Case presentation

We report the case of a 31 year-old male, heavy smoker, with no significant medical history, who presented to the orthopaedics clinic in our hospital for intense, continuous pain in the anterior region of the left ankle, with impaired walking. The pain, initially mild, dated for approximately one year in the absence of any noticeable trauma and was exacerbated by physical therapy. High doses of nonsteroidal anti-inflammatory drugs (NSAIDs) were used to control the pain. Upon physical examination, the tegument appeared normal with no signs of inflammation. The deep palpation in the external half of the articular space produced intense pain and revealed an area of slight tenderness.

Lateral incidence radiographic exam of the left ankle revealed a lytic area in the anterior margin of the distal tibial epiphysis corresponding to a vague round opacity of 1.5 cm in diameter. MRI studies showed a well delimited space-filling mass of 1.8/1.5/2.5 cm in the anterior synovial recess of the talocrural joint. The mass had a high contrast

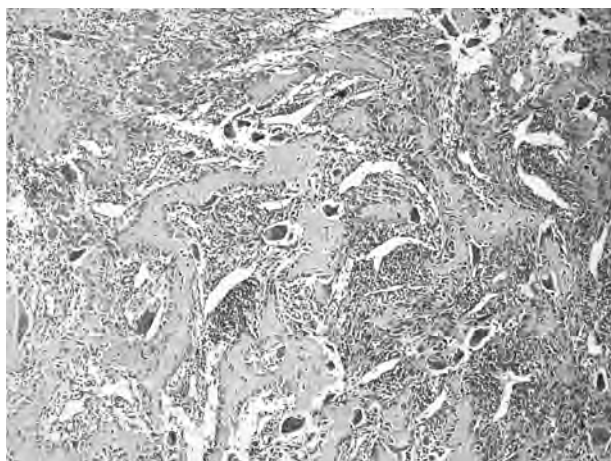
substance uptake, similar to the rest of the synovial membrane (figure 1). The signs and symptoms, radiology and MRI studies raised the suspicion of a synovial sarcoma.



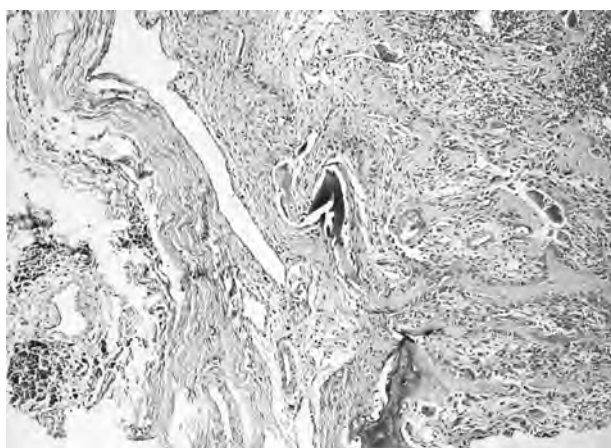
**Figure 1.** Tumor in the anterior synovial recess of the talocrural joint with contrast substance uptake similar to that of the rest of the synovial membrane (MRI)

During surgery, the sectioning of the articular capsule revealed a synovial mass, floating in the articular fluid, with a bone insertion on the lateral half of the anterior margin of the distal tibial epiphysis. The adjacent cortical bone was soft but apparently intact. The mass was brown in color, of elastic consistency, as best described by the surgeon as “similar to hepatic tissue.” A biopsy from the tumor was taken.

The histopathologic examination showed a proliferation of round/ovoid and spindle cells with vesicular nuclei and prominent nucleoli, marked deposition of thin woven bone trabeculae rimmed by prominent osteoblasts and areas with numerous bone-remodeling osteoclasts (figure 2). Some of the woven bone trabeculae were calcified. Rare typical mitoses (3 mitoses/10 HPF) were noticed. The stroma was rich in capillary-sized blood vessels, slit-like vascular spaces and extravasated erythrocytes. At the periphery, the tumor was partially covered in tenosynovial tissue with deposits of hemosiderin (figure 3).



**Figure 2.** Thin woven bone trabeculae rimmed by prominent osteoblasts; numerous osteoclasts; stroma with capillary-sized blood vessels and extravasated erythrocytes (HEx40)



**Figure 3.** At the periphery, tenosynovial tissue with deposits of hemosiderin (left side); calcified woven bone trabeculae (center) (HEx40)

Based on the microscopic aspects and on the clinicopathological correlations, the final diagnosis of HO was established. Therefore a local excision of the entire lesion was decided; no other supplementary treatments such as radical surgery, radiotherapy or chemotherapy were needed.

The whole specimen consisted of a tumor mass of 2.6/2.2/2.6 cm, brown color and elastic consistency. Its histopathology was similar to that of the biopsy specimen; however, a central, hypercellular, immature bone-formation area (figure 4) with focal bone maturation at the periphery was easily identified (figure 5), confirming the diagnosis of HO. No signs of local invasion were present. The patient is well, without any local recurrence of the disease or any movement impairment three years after the first presentation.

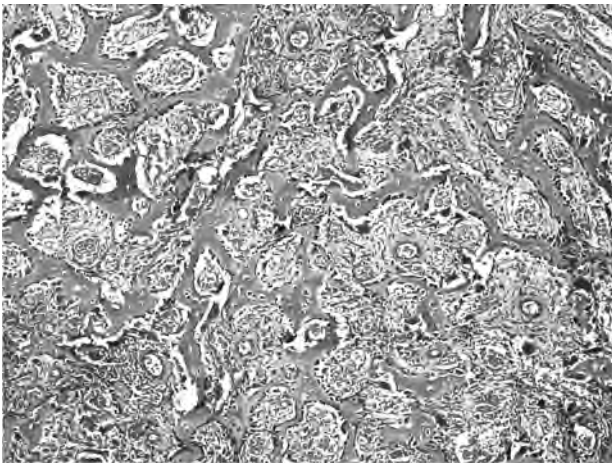


Figure 4. Immature bone-formation area (HEX40)

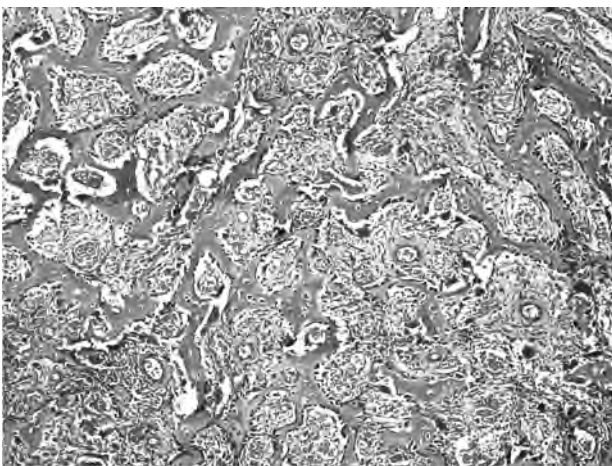


Figure 5. Bone maturation at the periphery of the lesion (center) (HEX40)

## Discussions

HO ossification is described in association with several types of conditions that for simplicity reasons can be grouped in three large categories.

The first category is represented by genetic and developmental forms of HO, including fibrodysplasia ossificans progressiva, progressive osseous heteroplasia, pseudomalignant HO, Albright hereditary osteodystrophy and parosteal fasciitis. Fibrodysplasia ossificans progressiva (FOP) is extremely rare, affecting less than 1 in 2 million persons [14] and it is characterized by congenital malformations of the great toes and a progressive HO with childhood onset.

The second group includes neurogenic HO (lesions appearing after spinal cord injury, traumatic brain injury, stroke and burns). HO following spinal cord injury was first described by Dejerine and Ceillier in 1918 as formation of mature lamellar bone in soft tissues around

paralyzed joints. About 10-20% of patients with spinal cord injury will develop HO [4].

The third category describes the most common condition, posttraumatic (either accidental or surgical) HO. A traumatic event can be identified in 60 to 75% of cases with no neurogenic or genetic causes, although spontaneous ossifications have been described [10]. High-energy wartime traumas of the extremities favor HO, especially when amputation or multiple extremity injuries are present or in settings of a high injury severity score [3]. Hip and acetabular surgery (either for total hip arthroplasty or acetabular trauma) quite frequently complicate with HO [1].

The mechanisms of HO development are not fully understood; most likely a local trauma elicits local inflammatory changes, thus triggering the differentiation of perivascular mesenchymal cells into osteoblasts; these newly differentiated osteoblasts begin the deposition of osteoid which eventually matures into lamellar, calcified bone [4]. Prostaglandin E2 (PGE-2) was demonstrated as the main inflammatory cytokine involved in HO formation, therefore nonsteroidal anti-inflammatory drugs are successfully used in HO prophylaxis (indomethacin, naproxen, diclofenac, celecoxib). [2,9]. Moreover, several studies in FOP reveal that bone morphogenetic proteins (BMP) have the potential to transdifferentiate myoblasts in culture into osteoblast-like cells; disequilibrium between BMP and BMP antagonists (either overexpression of BMP or underexpression of their antagonists) may initiate HO formation [12].

The diagnosis of HO is usually straightforward, based on clinical presentation and history: palpable mass plus gradually diminishing inflammatory symptoms after a precipitating event or clinical onset specific for neurogenic, genetic and developmental forms of HO. However, there are cases without any clinical hints – insidious symptoms of a growing mass in synovial location, as the case hereby reported; in these circumstances the most frequent clinical suspicion is that of neoplastic lesion, more likely a malignant tumor. Unfortunately, the histopathology picture is also prone to confusion, the reactive osteoblasts with plump nuclei and frequent mitoses rimming the newly deposited osteoid being easily mistaken as malignant.

Synovial sarcoma (SS) is the most frequent clinical diagnosis. SS affects young adults, frequently males, and it is located in the deep

soft tissues of the extremities, adjacent to joints, frequently around the knee; primary synovial involvement is rare – origin within a joint or bursa is demonstrated in seldom cases (incidence as low as 5% of cases) but possible. Clinical symptoms are unspecific with slow tumor growth. The histopathological appearance of SS is however very different to that of HO: SS is a biphasic or monophasic proliferation of epithelial and/or spindle cells, exceptionally associated with osteoid deposition [13]. However, in the cases of osteoid depositing SS, the osteoid is of lace-like type, not rimmed by osteoblasts, forming irregular lamellar and trabecular bone („osteosarcoma mimicking osteoid“).

Another clinical suspicion could be osteoid osteoma (OO) due to pain specifically controlled with NSAIDs. OO has a central nidus composed of sheets or microtrabeculae of osteoid lined by plump osteoblasts in vascularized connective tissue. OO is always a small, well circumscribed lesion (less than 1 cm in diameter) located within cortical bone; it has sharp, pushing borders and it is surrounded by sclerotic bone. Tumors with similar morphology but larger than 2 cm are labeled as osteoblastomas (OBs). Moreover, in rare cases, OBI may be located in periosteal tissue. Our patient displayed a large mass without cortical location, thus OO was excluded. The presence of woven bone rimmed by osteoblasts in the center of the lesion in highly vascular stroma is a characteristic for both lesions; however, the presence of maturation towards periphery identifiable in surgical specimen favors HO. The biopsy was more difficult to interpret but the heavy hemosiderin impregnation in the periphery of the lesion was a hallmark for previous intraarticular hemorrhages most likely due to trauma; one can speculate that hemorrhages may occur within the lesion since there is so much vascular density in the stroma; since the hemosiderin deposits have peripheral location it makes sense that a sequence hemorrhage - lesion (trauma induced HO) is more plausible than a sequence lesion - hemorrhage.

Osteosarcoma (OS) is another possible caveat, the burden of differentiation resting on the pathologist's shoulders. Low grade OS, giant cell rich type, is particularly difficult to rule out. OS is a bone-forming-tumor of young adults, frequently males, located in the metaphysis of long bones; ankle location for an OS is extremely rare but not impossible. The histopathological appearance

of giant cell rich low grade OS and HO may be similar: pleomorphic spindle cell proliferation with numerous osteoclasts with variable osteoid deposition. Larger specimens allow differentiation between OS and HO based on the presence of permeative/infiltrative tumor borders in OS and zonation of osseous maturation in HO (immature osteoid within the central area with osseous maturation towards periphery of the lesion). Small biopsies are prone to more difficult differential diagnosis due to the impossibility to analyze the entire architecture of the lesion; in this case the overall appearance of the osteoid is more helpful – highly variable thickness deposits of osteoid not rimmed by osteoblasts in OS versus woven bone trabeculae rimmed by osteoblasts and osteoclasts in HO.

Another lesion rich in osteoclasts with bone formation association is giant cell tumor of soft tissue (GCTSF). It is encountered in slightly older individuals than SS and OS, it involves superficial soft tissues of the upper and lower extremities; 30% of the cases are situated beneath the superficial fascia, a tenosynovial location being less probable. GCTSF is composed of a mononuclear round/spindle cell proliferation with numerous osteoclast-like giant cells in richly vascularized stroma; bone formation occurs in half of the cases and usually occurs as a shell of woven bone in the periphery, completely different from the bone deposition in HO.

Soft tissue lesions such as myositis ossificans (MO) may also concur to a differential diagnosis; MO affects young active patients with a mean age of 32 years, frequently males. It occurs in locations susceptible to trauma, within skeletal muscles. Its morphologic particularity is the “zonation” pattern, with a central immature, hypercellular zone, rich in fibroblasts, osteoclasts and myocytes, and a peripheral zone composed of trabeculae and sheets of woven bone rimmed by prominent osteoblasts; the overall histopathologic appearance of HO is somehow similar but the strict intraarticular location excludes a diagnosis of MO.

In conclusion, the cell proliferation was interpreted as benign fibroblasts which differentiate into osteoblasts with new, immature bone production, with extensive osteoclasts remodeling and maturation at the periphery. These aspects, correlated with the lack of invasion and the extraosseous location in tenosynovial tissue, certify the diagnostic of HO. Because in this case

no precipitating event was identified, the HO could be classified as idiopathic, a type which is rarely reported in the literature [8].

**Acknowledgements:** *We are grateful to prof. dr. Pieter Slootweg, UMC St Radboud Nijmegen, the Netherlands for providing second opinion in this case.*

## References

1. Baird EO, Kang QK - Prophylaxis of heterotopic ossification - an updated review. *J Orthop Surg Res.* 2009;4:12.
2. Fijn R, Koorevaar RT, Brouwers JR - Prevention of heterotopic ossification after total hip replacement with NSAIDs. *Pharm World Sci.* 2003;25:138-45.
3. Forsberg JA, Peppek JM, Wagner S et al - Heterotopic ossification in high-energy wartime extremity injuries: prevalence and risk factors. *J Bone Joint Surg Am.* 2009;91:1084-91.
4. Jacobs JWG, De Sonnaville PBJ, Hulsmans HMJ, Van Rinsum AC, Bijlsma JWJ - Polyarticular heterotopic ossification complicating critical illness. *Rheumatology*, 1999;38:1145-1149
5. Kaplan, F - Heterotopic Ossification. *JAAOS.* 2004;12:116-125
6. Kluger G, Kochs A, Holthausen H - Heterotopic ossification in childhood and adolescence. *J Child Neurol.* 2000;15:406-13
7. Kun EW, Barr WG - Heterotopic ossification presenting as acute arthritis. *J Rheumatol.* 1992;19:994-6
8. Lane JE, Dean RJ, Foulkes GD, Chandler PW - Idiopathic heterotopic ossification in the intensive care setting. *Postgraduate medical journal* 2002 78, 494-495
9. Macfarlane RJ, Ng BH, Gamie Z et al - Pharmacological treatment of heterotopic ossification following hip and acetabular surgery. *Expert Opin Pharmacother.* 2008;9:767-86.
10. Karam MD, McKinley TO - Traumatic Heterotopic Ossification of the Quadratus Lumborum: A Case Report. *The Iowa Orthopaedic Journal* 2008;28:88-90
11. Mccarthy, E - Heterotopic Ossification: A Review. *Skeletal Radiol.* 2005;34:609-619.
12. Morrissy RT, Weinstein SL - Lovell and Winter's Pediatric Orthopaedics 6ed., 2006 Lippincott Williams & Wilkins
13. Hara S, Hatori M, Hosaka M, Komatsu T, Tsuchiya T, Kimura N - Synovial sarcoma with massive ossification - A Case Report. *Upsala J Med Sci* 2003;108:151-158
14. Hamilton, SW; Roxburgh C; Renshaw PR - Fibrodysplasia ossificans progressiva: a new spotlight on an old disease—a case report. *Acta Orthopaedica*, 2008;79:449-451