



PROMISING RESULTS WITH RITUXIMAB IN A CASE OF SEVERE SYSTEMIC ARTHRITIS - JUVENILE IDIOPATHIC ARTHRITIS REFRACTORY TO MULTIPLE DRUGS

N. Iagăru, A.V. Cochino

University of Medicine and Pharmacy "Carol Davila", Pediatric Clinic/Mother and Child Healthcare Institute "Alfred Rusescu" Bucharest

Abstract. Background. Systemic arthritis belongs to a heterogeneous group of pediatric rheumatic diseases known as juvenile idiopathic arthritis (JIA). This subtype is defined by extraarticular signs which, even today, lead to diagnosis without specific lab tests. Patients with systemic arthritis (sJIA) also have a range of other prominent features, including elevation of erythrocyte sedimentation rate (ESR) and C-reactive protein (CRP), leukocytosis with high neutrophil counts and thrombocytosis. Ferritin concentrations are high and correlate with systemic disease activity. Systemic arthritis is often extraordinarily resistant to treatment with steroids, methotrexate, etanercept, etc. We will present one such case, with persistent evolution refractory to multiple conventional and biological remissive drugs..

Keywords:

Background

Systemic arthritis belongs to a heterogeneous group of pediatric rheumatic diseases known as juvenile idiopathic arthritis (JIA). This subtype is defined by extraarticular signs which, even today, lead to diagnosis without specific lab tests. Patients with systemic arthritis (sJIA) also have a range of other prominent features, including elevation of erythrocyte sedimentation rate (ESR) and C-reactive protein (CRP), leukocytosis with high neutrophil counts and thrombocytosis. Ferritin concentrations are high and correlate with systemic disease activity. Systemic arthritis is often extraordinarily resistant to treatment with steroids, methotrexate, etanercept, etc. We will present one such case, with persistent

evolution refractory to multiple conventional and biological remissive drugs.

Case

D.G., 17 y.o., Caucasian female, rural origin, is admitted to our hospital beginning with 17.05.2005, for longer (even 3 month!) or shorter periods of time (every month since then).

The admission reasons were almost the same every time: fever 39-40.5°C, chills, rash, polyarthritis and malaise.

History. The patient was diagnosed with Systemic Onset -JIA at 9 y.o. (fever, rash, hepatosplenomegaly, pericarditis and oligoarticular arthritis). After 6 months of treatment with prednisone, remission was obtained and it was persistent for 5 years. She relapsed in 07.05.2005 when she came to our hospital with fever (39.5-40.5°C), chills, evanescent rash, polyarthritis, generalized lymphadenopathy, hepatosplenomegaly and progressive malaise.

Personal and family history. Normal data concerning growth and functional milestones. Patho-

Nicolae Iagăru MD, PhD

IOMC "Alfred Rusescu", 120 Lacul Tei, Boulevard,
sector 2, Bucharest,
E-mail: iagarun@yahoo.com

logic personal history: Atrial septal defect diagnosed at 9 y.o., spontaneously closed before 14 y.o.

Family history: Mother: 40 y.o.; father: 46 y.o.; 2 healthy brothers; no rheumatic diseases in the family.

Clinic exam after relapsing (17th May 2005): malaise, chills, fever 39.5°C, arthralgias (bilateral knees and ankles) and myalgias; generalized moderate lymphadenopathy and discrete hepatomegaly. One week after admission the patient presents an evanescent maculoerythematous rash on thorax, face, limbs and a facial rash (cheeks, nose bridge). After a month she presents right wrist and left ankle arthritis and then swelling of the 2nd left costochondral junction. Arthralgias become generalized. In evolution she complains of precordial pain which, together with the echographic exam (small amount of liquid in pericardial sac) lead to the diagnosis of pericardial serositis. At the same time, she presented fixed erythematous, hard, tender plaques on the shanks and forearms (next to wrist and ankle joints) different as aspect and persistence (weeks!) from the characteristic rash of systemic arthritis. (Figure 1)

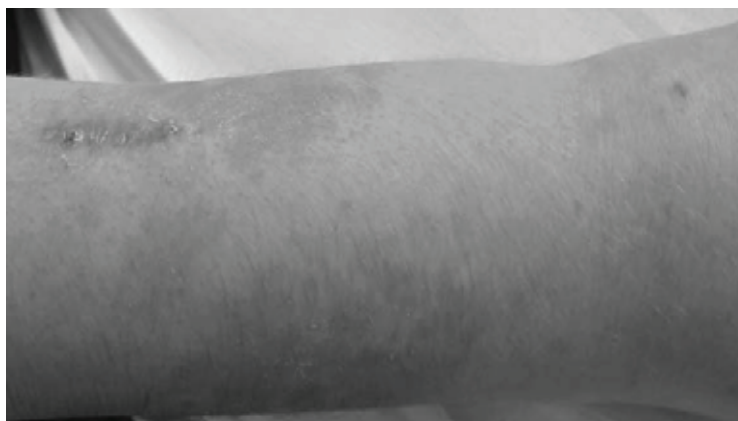

Figure 1. DG 14 yo indurated erythematous plaques next to right wrist joint (next to the linear scar after skin biopsy)

Lab exams. They were constantly characterized, from the beginning of the second evolutive cycle, by an important inflammatory syndrome with ESR of 126 mm/h, CRP 34.5 mg/dL, serum fibrinogen 1000 mg/dL, hyperleukocytosis (25.000-30.600/mm³) with neutrophilia (80,5%). Thrombocytosis (750.000/mm³) and hyperferritinemia (2294 ng/ml) complete the characteristic features of systemic arthritis.

For **differential diagnosis** the following tests were performed: blood cultures (sterile), bone marrow exam (reactive bone marrow, no atypia),

antinuclear antibodies (ANA) and anti-double-stranded DNA (anti-dsDNA) antibodies (negative), anti-Scl 70 autoantibodies and anti-centromere antibodies (negative), anti-smooth muscle antibodies (negative), muscular enzymes (normal CK), normal transaminases (ALT, AST), HBs antigen, HVC, EBV and HIV antibodies (negative), abdominal ultrasonographic exam (normal).

Rheumatoid Factor (FR) was constantly negative. Cardiac ultrasonography shows small amount of liquid (5mm in the pericardial sac anterior to the right ventricle, 2 mm posterior to the left ventricle). Slit lamp examination of the anterior eye pole was constantly normal.

Periungual capillaroscopy was quasinormal and skin biopsy was slightly suggestive for a possible scleroderma or an infectious process but special stainings deny morphea supposition (These tests were needed because of certain *scleroderma-like* skin lesions, suggesting a possible JIA/SD overlap syndrome).

Anamnestic, clinic and lab findings confirm the diagnosis of systemic arthritis – second evolutive cycle.

Due to severe and persistent (between 17 May 2005 and 17 March 2006, the patient was in the hospital for 221 days !) articular and, especially, extraarticular symptoms and due to biological inflammatory syndrome, we tried almost every conventional therapeutic schemes and also two biologic agents (Table I).

Evolution

In the 3 years following the relapse, the evolution was catastrophic, despite therapeutic efforts:

| | |
|------|---|
| I. | 2005-2008- steroids: Prednisone (starting dose 2 mg/kg/d gradually reduced at 2-3 weeks); Methylprednisolone (pulse therapy, over 20 series of 3 days, in dose of 30 mg/kg/d) |
| II. | 2006 (6 months): Etanercept (0,4 mg/kg/2 dose/week sc) and high dose MTX (25mg/week, po). Severe adverse effect: toxic pneumonia (MTX), healed after 3 weeks |
| III. | 2006 (6 months): Cyclosporine A 5 mg/kg/day. |
| IV. | July 2006-May 2007 (10 months): Infliximab (5 mg/kg/dose IV every other month) and Azathioprine (3 mg/kg/d). |
| V. | 2007 (2 months): Leflunomide (10 mg/d). |
| VI. | 2007-2008: Rituximab (500mg/dose iv: 11/09 and 26/09/2007; 1000 mg/dose: 11/04 and 23/04/2008) |
| VII. | 2008, April to date: MTX 15 mg/week, Leflunomide 10 mg/d, Prednisone 5 mg/d and Etoricoxib (1 tb/d) |

Table I.

high persistent fever, evanescent rash, *scleroderma-like* plaques for several months in 2006 (Figure 1), hepatosplenomegaly, cachexia (weight loss of 15 kg, from 48kg in 2005 to 33kg in 2007), secondary amenorrhea, severe anemia (Hb=6.8g/dL), hypoalbuminemia (2.1g/dL), osteoporosis (BMD L2-L4=0,744g/cm; Z=3,305g/cm) with loss of T12 and L1 vertebral body height; she had violent radicular pain and she was bedridden in 2006). Her symmetric polyarthritis affected over 30 joints (all big joints, metacarpophalangeal and proximal interphalangeal joints, first left metatarsophalangeal joint, 2nd left costochondral junction, and even the

over 100mm/h, CRP over 200-250 mg/L, leukocytes over 20.000/mm³ with neutrophilia over 75%).

Wrist x-rays examination (after 8 months of evolution): the entire radiocarpal and metacarpal region had remarkable bone demineralization and diminished joint spaces, but with preserved bone integrity. Poznanski index was under 2 SD.

Articular ultrasonography: small amount of intraarticular liquid (knees and wrists). Hence, the walking became very difficult, possible only with support, and attending school was impossible. In June 2008 she was 35 kg weight and 156 cm height (Table II).

| Date | T (°C) | G (kg) | Joints affected | | DAS 28 3v |
|------------|--------|--------|--|---|-----------|
| | | | Joints with active arthritis (Total no.) | Joints with impaired movement (Total no.) | |
| 30/01/2008 | 39,5 | 33,5 | 33 | 33 | 8.97 |
| 15/02/2008 | 39,5 | 34 | 35 | 35 | 9.13 |
| 05/03/2008 | 39-40 | 33 | 35 | 35 | 9.20 |
| 09/05/2008 | 41,5 | 35 | 20 | 22 | 7.71 |
| 20/06/2008 | 38 | 35 | 20 | 22 | 7.14 |
| 14/08/2008 | 37 | 38 | 2 | 22 | 5.69 |

Table II.

cervical spine). Ankylosis in flexion has gradually developed especially in knees, ankles, wrists, elbows and in the proximal interphalangeal and metacarpophalangeal joints (Figure 3 and 4.)

Biologic inflammatory syndrome persisted during all this time with extremely high values (ESR

The general aspect revealed a very ill, pale, cachectic, very depressive adolescent female. In June 2008 the CHAQ score was 16 (2), and DAS 28 3v score was 5.69 (Table II). The cardiac ultrasonography performed in 2007 showed endocardial calcification on anterior mitral valve and on the

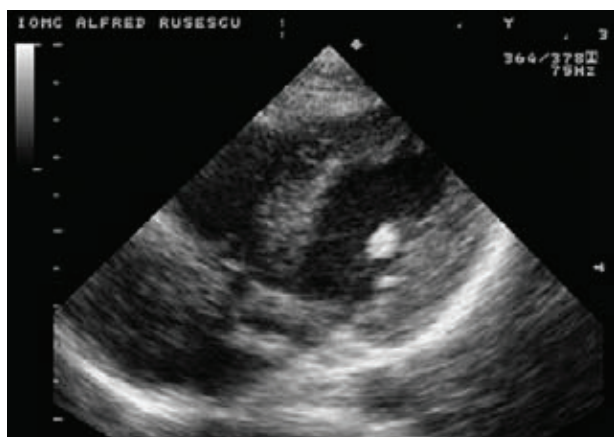


Figure 2. DG 17 y.o. endocardial calcification
(by courtesy of Prof. Dr. Ioana Anca)

right ventricle moderator band, suggestive for a possible previous endocarditis (Figure 2).

A slight clinic and biologic improvement began in June 2008, 2 months after the second cure with rituximab 1000 mg IV. (Table III). This improvement was not seen after the first two infusions of 500 mg rituximab, previously given, despite the persistent B lymphocytes depletion (<1%).

In the last 3 months the patient received: MTX 10mg/week (the avoidance of high doses was dictated by previous toxic pneumonia), Arava (Leflunomide) 10mg/d, Arcoxia 60mg (Etoricoxib) 1 tb/d, Tardyferon (Ferrous sulfate 80mg) 1tb/d, Rocaltrol 0,25µg (Calcitriol) 2tb/d, Calcium lactate 1,5g/d, Actonel (Risedronate sodium) 5mg/d, Miacalcic (Calcitonin 50ui/ml) 1 vial/week. In the meantime she attends physical and kinesiotherapy programs.

Discussion

Polycyclic evolution of the systemic arthritis involves relapses, sometimes for long periods of

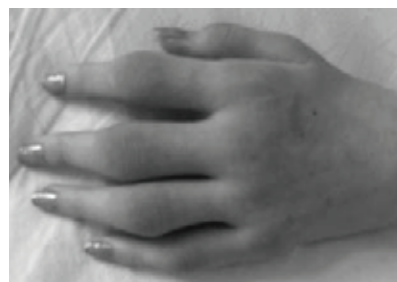

Figure 3. DG 17 yo, 2008: Active arthritis of proximal interphalangeal and metacarpophalangeal joints

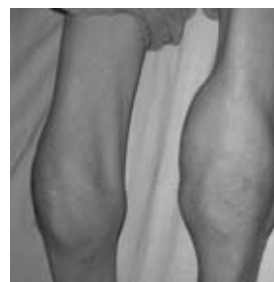


Figure 4. DG 17 yo, 2008: Active arthritis on the knees with proximal and distal muscle atrophies

time, even years [1]. In these cases the relapses can occur even in adult age. Approximately 34% of the patients can present this evolution type [2]. Our patient's two periods of disease's intense activity seem to confirm this type of evolution. The continuous 3 years evolution of the second cycle suggests the persistent type of the disease. The remission definition of the JIA, still under debate, includes, along with absence of medication for 12 months: 1) no fever, rash, adenopathies, hepatosplenomegaly or serositis; 2) absence of active arthritis; 3) ESR and CRP in normal range; 4) the best possible score after doctor's evaluation [3]. In our case none of these criteria was fulfilled, even though in the last 3 months there was a remarkable improvement (Tables II and III). The probability of the overlap syndrome, suggested by the presence of certain

| Date | CRP (mg/L) | Hb (g/L) | ESR (mm/h) | Leukocytes (x 10 ⁹ /l) | Albumin (g/L) | Ferritine (µg/L) | IgG (g/L) |
|------------|------------|----------|------------|-----------------------------------|---------------|------------------|-----------|
| 30/01/2008 | 250.0 | 96 | 116 | 10.87 | 24 | 2294 | 16.34 |
| 15/02/2008 | 245.0 | 93 | 118 | 8.98 | 21 | | |
| 05/03/2008 | 180.0 | 84 | 129 | 8.01 | 20 | 1781 | 18.18 |
| 23/04/2008 | | 110 | 116 | 10.06 | | | |
| 09/05/2008 | 210.2 | 99 | 85 | 9.36 | 25 | | |
| 20/06/2008 | 121.5 | 120 | 40 | 11.97 | | | |
| 14/08/2008 | 204.0 | 120 | 20 | 7.39 | 35 | 932 | |

Table III

scleroderma-like skin symptoms, was not confirmed either histopathologically or immunologically (absence of anti-Scl 70 and anticentromere antibodies). Although systemic features (fever, rash, pericarditis), as generally described in field literature, became mild in the first months or years of the disease (2 to 5 years! [4]), the absence of remission after such a long time in the biological therapy era (failure of etanercept combined with MTX, and also, infliximab combined with azathioprine) rather suggests a persistent systemic arthritis / JIA (~55% of cases [2]) and “treatment needed for indefinite period of time” [3]. In addition to cytokine blockade, the B-cell-targeted therapy with rituximab, a chimerical anti-CD20 monoclonal antibody, is now successfully used in Rheumatoid Arthritis [6, 7, 8]. We used four rituximab infusions (500 mg on days 1 and 15 for the first series, and 1000 mg for the next two infusions after 6 months, with methylprednisolone 100mg IV, given as pre-medication) to treat this refractory case of systemic arthritis. The remarkable clinical and biological improvement, noticeable 4 months after the second series of rituximab, was very encouraging: ESR, CRP, and DAS 28 had significantly fallen (see Table II and III). Unfortunately, because of the lack of studies and approvals (FDA, EMEA, National Authority for Drugs) we stopped this treatment, although cases successfully treated with rituximab sporadically go on [9, 10, 11]. For the near future, we have two theoretical possibilities: 1) the patient will be included in a tocilizumab treatment protocol [5], which is hoped to have better results, due to the major role of IL-6 in the systemic JIA (but also unapproved yet for JIA); 2) wait for the 18 y.o. of age to legally continue the rituximab treatment recommended by the rheumatologists for adults.

In conclusion, this report of a JIA case refractory to conventional DMARDs and biological agents reflects the limits of our therapeutic means, especially in systemic arthritis. We wait for an imperative fortification of biological antirheumatic

arsenal for systemic arthritis through new drugs like tocilizumab, and, why not, rituximab.

References

1. **Prieur Anne-Marie, Malleson PN, Kimura Yukiko.** Systemic arthritis in Arthritis in Children & Adolescents. *Ed. by Szer, Kimura, Malleson, Southwood; Oxford University Press 2006 :210-222*
2. **Lomater C, Gerloni V, Gatinara M, et al.** Systemic onset juvenile rheumatoid arthritis: A retrospective study of 80 consecutive patients followed for 10 years. *J Rheumatol 2000; 27:491-496*
3. **Wallace CA, Ruperto N, Giannini E.** Childhood Arthritis and Rheumatology Research Alliance; Pediatric Rheumatology International Trials Organization: Pediatric Rheumatology Collaborative Study Group. Preliminary criteria for clinical remission for select categories of juvenile idiopathic arthritis. *J Rheumatol 2004;31:2290-2294*
4. **Petty RE, Cassidy JT.** Systemic Arthritis. In *Textbook of Pediatric Rheumatology, Cassidy, Laxer, Lindsley; 5th Edition 2005:291-303*
5. ***** F.HOFFMAN-LA ROCHE LTD.** Tocilizumab Compassionate Use Programme-Guidance for Structured Assessment. Systemic Onset Juvenile Idiopathic Arthritis (**Personal communication, 2008**)
6. **Cohen SB, Emery P, Greenwald MV, et al.** Rituximab for Rheumatoid Arthritis Refractory to Anti-Tumor Necrosis Factor Therapy. *Arthritis & Rheumatism, Vol.54, No.9, September 2006, pp 2793-2806*
7. **Smolen JS, Keystone EC, Emery P, et al.** Consensus statement on the use of rituximab in patients with rheumatoid arthritis. **Published Online First 20 December 2006.** *www.annrheumdis.com The EULAR Journal*
8. **Emery P, Fleischmann R, Filipowicz-Sosnowska A, et al.** The Efficacy and Safety of Rituximab in Patients With Rheumatoid Arthritis Despite Methotrexate Treatment. *Arthritis & Rheumatism Vol.54, No.5, May 2006, pp 1390-1400*
9. **Kuek A, Hazleman BL, Gaston JH, Ostor JK.** Successful treatment of refractory polyarticular juvenile idiopathic arthritis with rituximab. *Rheumatology 2006 45(11):1448-1449*
10. **Baildan EM, Saladi S.** Rituximab in ANA positive polyarticular juvenile idiopathic arthritis (JIA) with uveitis. *Pediatric Rheumatology 2008, 6(suppl):P71 (poster presentation)*
11. **Kosher-Meron M, Uziel Y, Amital H.** Successful treatment with B-cell depleting therapy for refractory systemic onset JIA: a case report. *Rheumatology 4, January 22, 2009*