



## CONTROVERSIES IN LATE NEUROBORRELIOSIS AND MULTIPLE SCLEROSIS – CASE SERIES

Amanda Rădulescu<sup>1</sup>, Doina Țătulescu<sup>2</sup>, Lăcrimioara Perju-Dumbravă<sup>3</sup>, Mirela Flonta<sup>4</sup>,  
Augusta Aștilean<sup>5</sup>, Melinda Horvat<sup>2</sup>

<sup>1</sup> The “Iuliu Hațieganu” University of Medicine and Pharmacy, Cluj-Napoca, Department of Epidemiology,

<sup>2</sup> The “Iuliu Hațieganu” University of Medicine and Pharmacy, Cluj-Napoca, Department of Infectious Diseases

<sup>3</sup> The “Iuliu Hațieganu” University of Medicine and Pharmacy, Cluj-Napoca, Department of Neurology

<sup>4</sup> The Laboratory - the University Hospital of Infectious Diseases Cluj-Napoca

<sup>5</sup> Resident in the specialty of Infectious Diseases

---

**Abstract. Introduction.** The etiology of MS remains uncertain, bacterial infection with *B. burgdorferi* is most frequently incriminated. Neuroimaging criteria considered in the diagnosis of MS can also be fulfilled in NB, the joint feature being demyelinating lesions. We present the diagnosis and treatment difficulties in NB versus MS and other clinical considerations.

**Methods** We retrospectively studied all consecutive cases of neuroborreliosis hospitalized in the University Hospital of Infectious Diseases during 2006-2008. The diagnosis was established through clinical criteria (using a probability score for Lyme disease), serological criteria (enzyme immunoassay for IgM and IgG antibodies followed by confirmatory Western blot) and MS diagnosis was stratified as confirmed or possible according to MacDonald's criteria.

**Results** There were 36 cases of probable or highly probable neuroborreliosis (score  $\geq 6$ ), out of which ten cases were also diagnosed as possible (5) or confirmed MS (5). The age range was 19 to 43 years, with female predominance (7/10). The clinical picture was marked by poor stamina and fatigue, paresthesia mainly in the lower extremities, palsies (facial or in the limbs), difficult walking and vertigo. In all cases the screening enzyme immunoassay was positive for IgM antibodies, confirmatory Western blots were positive in four out of seven tests performed. Tick exposure was identified in 5 cases without erythema migrans. In all patients cerebral imaging examination revealed demyelinating lesions that were interpreted as late NB and/or MS (possible or confirmed). Treatment with neurotropic drugs and antibiotics was done and the five patients with confirmed MS received beta interferon or corticosteroids. All cases demonstrated improvement after 6 weeks of sequential treatment (ceftriaxone and doxycycline). In one case, the diagnosis of cerebral lymphoma was considered suggesting the association between NB and MS or neuroborreliosis mimicking primary effusion lymphoma.

**Conclusions.** The diagnosis of MS and NB are difficult showing remarkable clinical and neuroimaging similarities. The infectious etiology of MS remains probable and in patients with possible MS it is reasonable to evaluate *B. burgdorferi* infection in order to ensure etiologic treatment.

**Keywords:** *Borrelia burgdorferi*, multiple sclerosis, neuroborreliosis

---

---

### Amanda Rădulescu MD, PhD

The “Iuliu Hațieganu” University of Medicine and Pharmacy, Cluj-Napoca,  
Department of Epidemiology  
Tel: 0040264 594655 Fax: 0040264 430444  
E-mail: aradulescu@umfcluj.ro

### Abbreviations:

MS – multiple sclerosis, NB – neuroborreliosis,  
Wb - Western blot, CNS – central nervous system,  
*B. burgdorferi*- *Borrelia burgdorferi*, HSPs - heat shock proteins, MRI – magnetic resonance imaging,  
ACA - acrodermatitis chronica atrophicans

---

### Premises upon causal association between chronic neuroborreliosis and multiple sclerosis

The etiology of MS, autoimmune demyelinating disease of the CNS remains unknown but is believed to involve 3 factors: genetic vulnerability, environmental exposures (pathogen triggers) and the development of pathologic host immune response directed against CNS (9). Afflicting adolescents and young adults (age range 15-50 years), the chronic disease often takes a disabling course and there is neither prevention nor a cure for MS. The infectious etiology was presumed by Pierre Marie from 1884 and it was experimentally proved by Adams in 1925 (rhesus monkeys). Gabriel Steiner demonstrated the presence of microorganisms spirochetes-like in the brain tissue from patients deceased due to MS in 1952. There is evidence that cystic L-forms of *B. burgdorferi* may cause persistent infection including MS. These cystic forms present as argyrophilic granules and are considered to be starvation forms of the spirochaetes. In 2001, Brorson *et al.* isolated cystic structures originating from spirochetes in 8 out of 10 Norwegian MS patients by means of immunofluorescence and in all 10 patients by transmission electron microscopy. The cysts of the MS patients exhibited positive reactions to anti-borrelia antiserum and, after culturing, curved spirochaete-like bacteria emerged and could then be propagated. The authors demonstrated the first three Koch's postulates and also observed that transformation of the *B. burgdorferi* into cystic forms occurred invariably after inoculation in the cerebrospinal fluid (CSF) [5]. Besides fundamental studies there is epidemiological correlation between borreliosis and MS. Worldwide, MS prevalence parallels *B. burgdorferi* sensu lato endemicity. The frequency of NB and MS decreases from the 37°C latitude to the Equator and their spread to regions where previously never described was related to the routes of the migratory seabirds. The speculation is that in America and Europe, the birth excesses of those individuals who later in life develop MS exactly mirror the seasonal distributions of *B. burgdorferi* transmitting *Ixodes* ticks at the time of birth. The geographical gradient almost demonstrating the absence of MS between the tropics where treponematoses are frequent can be explained by different expression of the HSPs. These proteins protect bacteria against temperature fluctuations and also activate the host immune defenses. *Treponema*, being an exclusively human pathogen, could afford to delete the capacity of heat shock resistance while

*Borrelia* spp. should be adapted to a broad range of changes in temperature by expressing HSPs. *B. burgdorferi*, intracellular pathogen, sequesters cytosolic HSP 90 and other HSPs therefore, not surprisingly, auto-antibodies can be demonstrated against HSP during such infections as well as in patients with MS. The inflammation mechanisms in autoimmune disorders are similar to those from chronic diseases. The immune response is not able to remove the offending agent; auto-antigens are released from damaged tissues thus amplifying the auto-aggressive response. The CNS contains numerous candidate auto antigens among which myelin basic protein and members of the HSP family are worth mentioning, HSP 70 being involved in myelin folding. Inflammatory demyelination during the evolution of MS increases the permeability of the blood brain barrier and is followed by a focal infiltration of lymphocytes around small blood vessels in the brain; these inflammatory cells might be a reaction against infectious antigens. The cerebral tissue has a deficient capacity for initiating a primary immune response and clearance of intracellular pathogens favoring chronic or relapsing neurological infections. Worse, CSF contains nutrients and less than 1% of complement and circulating antibodies therefore most of the plaques are periventricular although any part of the CNS can be affected [5, 9, 20, 22].

The MS diagnosis is far from being simple, besides asymptomatic forms, based on autopsy studies (~20%), the most common clinical forms are relapsing remitting type (55% of overall MS) and 10% are primary progressive. Symptoms suggestive of MS are: relapses and remissions, onset between ages 15 and 50, long lasting paresthesia of arm and leg, diplopia, ophthalmoplegia, vision loss, subacute motor deficit, gait disturbance, vertigo, Lhermitte's sign, fatigue [14,17,22]. To increase the specificity of diagnosis and to minimize over diagnosis laboratory criteria are used: magnetic resonance imaging, evoked potentials and CSF analysis. Conventional MRI techniques detect white matter lesions in 90% of the cases: T2 hyperintense (with no specificity), T1 hypointense (greater damage) and gadolinium contrast enhancing lesions (focal current disease activity). MRI is very sensitive and specific for predicting evolution to clinically definitive MS but it is difficult to explain why severe lesions remain (sometimes) without clinical symptoms [14,17]. In the CSF the most important is immunoglobulin analysis: IgG index and detection of oligoclonal bands (subsets of antibodies against unknown an-

tigens that might be the result of chronic viral or bacterial infections). Visual evoked potentials test is used to detect abnormal CNS function. Poser and MacDonald's diagnosis criteria and Barkhof's criteria applied in clinically isolated syndrome allow the diagnosis of definite or probable MS [17,19]. Differential diagnosis includes: autoimmune disorders, neurosarcoidosis, ischemic lesions, thromboembolic events, vasculitis, postinfectious or vaccine-associated encephalomyelitis and NB. Confirmatory diagnosis is mostly clinical (two or more attacks with 2 or more objective clinical lesions); probable MS combine one or two attacks with additional data [5,9,14,17,19]. It is known that persistent viral or bacterial infection triggers and amplifies autoimmune disorders. Among bacterial infections *B. burgdorferi* sensu lato was considered related to SM. The persistency and the ability to escape or to suppress the immune response have many explanations:

other spirochetal diseases, *B. burgdorferi* infection manifests in stages with relapses and remissions. **Early disease** occurs in less than 80% of infected individuals, 4 days after exposure (3-32 days), erythema migrans is characteristic. Small ticks (*Ixodes scapularis*), minimal or atypical lesions might not be observed. Hematogenous dissemination of *B. burgdorferi* sensu lato to the nervous system, joints, heart or other skin areas may give rise to a wide spectrum of clinical manifestations. **Late borreliosis** may develop among some untreated patients months to a few years after tick-transmitted infection. The major manifestations of late borreliosis include arthritis, late NB (peripheral neuropathy or encephalomyelitis) and ACA. While Lyme arthritis is the most common late manifestation of LB in North America, ACA appears to be the most common manifestation of late borreliosis in Europe [1, 8, 24] (table I).

	Early NB	Late NB
<b>Onset</b>	Acute	Latent
<b>Central nervous system manifestations</b>	Acute meningitis Acute encephalomyelitis	Lyme encephalopathy Encephalomyelitis
<b>Peripheral nervous system manifestations</b>	Radiculoneuritis Cranial nerve involvement	Chronic radiculoneuropathy
<b>CSF-pleiocytosis</b>	75-80%	Only in 5% of CNS manifestations and absent in peripheral neuropathy
<b>Positive serology</b>	80-90%	> 50% in CNS manifestations, rarely positive in peripheral neuropathy
<b>Treatment results</b>	Excellent	Variable

**Table I** Characteristics of early and late borreliosis

- genetic diversity and differential expression of the antigens that spirochete express in mammalian hosts (OspC, other gene products – VlsE),
- production of a protective layer (e.g. a capsule as that seen in *T. pallidum*);
- producing cystic forms (L- forms),
- inducing incomplete or modified immune response,
- presence of pathogenic factors allowing immune evasion: motility, host proteases used for invasion, deleterious activity on neutrophil function, differential expression of the Toll-like receptors, breaking through barriers (e.g. brain barrier etc.) [16,18].

The diagnosis of the early disease is clinical since erythema migrans is the hallmark of Lyme borreliosis. In late disease no laboratory test is validated to definitely confirm the diagnosis. As

Chronic borreliosis and its treatment differ substantially from the diagnosis and treatment of other infectious diseases. The diagnosis is often based solely on clinical judgment rather than on well-defined validated laboratory studies. Late borreliosis diagnosis is supported by: clinical picture of at least one year, arthritis and/or neurological manifestations, active infection with *B. burgdorferi* regardless of previous treatments. Structural neuroimaging may not be relevant as many patients will have normal examination but recent prospective studies reported small areas of abnormality in the white matter similar to those seen in MS mainly if focal symptoms were present [3,11].

**Methods**

We retrospectively studied all cases of NB hospitalized in the University Hospital of Infectious Diseases between 2006 - 2008. Diagnosis was

based upon clinical criteria (including neurological evaluation) and serological testing (ELISA for IgM and IgG followed by confirmatory immunoblot) [7,13,24]. The immunoblotting assay was interpreted as positive for IgM if reactivity to OspC, VlsE and p39 antigens was present and as positive for IgG if reactivity to VlsE, p 83 and other antigens was present. For each case a probability score was calculated based upon exposure, clinical and serological criteria thus generating a stratified diagnosis: very probable Lyme disease with 7 or more than 7 points, probable with 5-6 points and not probable if score was 4 or less. The score includes:

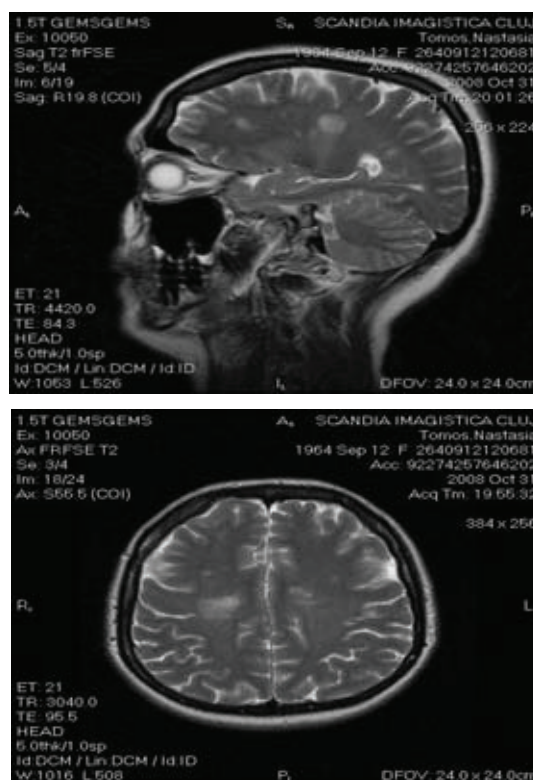
Tick exposure	1
History of disease suggestive for borreliosis	2
Systemic involvement with exclusion of other diagnosis	
- one system e.g. arthritis	1
- two systems, e.g. arthritis and facial palsy	2
Erythema migrans confirmed by physician	7
Achrodermatitis chronica atrophicans confirmed through biopsy	7
Seropositivity / Seroconversion	3 / 4
Silver stain microscopy / IFA	3 / 4
Positive cultures	4
Identification of Borrelia antigens	4
Identification Bb DNA/RNA	4

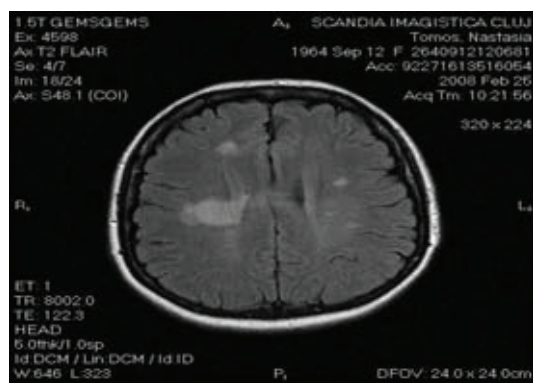
Every case of possible, confirmed MS or presenting a clinically isolated syndrome (according to McDonald's criteria and to Barkhof criteria) referred to our clinic was evaluated and the diagnosis of very probable or probable NB was established [17, 22].

## Results

Among the 36 cases of neuroborreliosis with probability scoring  $\geq 6$ , ten were also diagnosed with possible MS (5 being coincidentally evaluated for neuroborreliosis) or confirmed relapsing remitting MS (5 MS cases diagnosed before NB evaluation). The range of age was 19 to 43 years, with female predominance (7/10). The referral process was mainly from neurology wards. The diagnosis of late NB was sustained by: tick exposure (found in 5 cases, none with erythema migrans, 1 to 11 years before the onset of neurological disease). The clinical picture consisted of: fatigue, poor stamina, long lasting paresthesia of arm and leg (all cases), subacute motor deficit (arm or leg or facial palsy in 6 cases), vertigo (3 cases), extrapyramidal syndrome (one case), chromatic visual disturbance (one case), transient sphincter control disorder

and one without any objective neurological signs. In all cases immunoassay testing was positive for IgM and negative for IgG (except one case with both tests reactive). Confirmatory WB was not always available, there were four confirmed cases among seven tested. In three cases diagnosed with possible MS, cerebrospinal fluid was analyzed and did not show specific modifications. In all cases neuroimaging demonstrated the presence of one or more brainstem lesions: hyperintense on T2 MRI and FLAIR (fluid-attenuated inversion recovery), hypointense on T1 MRI found periventricular, in the white substance, frontal lobe and in the pons, oedema was never present. We present the case of a 43-year old woman with documented tick exposure without erythema migrans occurring in 2006. In January 2008 she was diagnosed with MS and treatment with metilprednisolon was initiated due to coexisting autoimmune tiroiditis. At the first admission the clinical picture consisted of fatigue, motor deficit in the left body. Serology was positive for IgM Wb confirmed and she presented numerous MRI lesions. She was treated twice with ceftriaxone 21 then 14 days, respectively followed by doxycycline. In November 2008, after antibiotic treatment she was asymptomatic despite important cerebral lesions. One of the lesions looked remarkably similar to primary CNS lymphoma. Epstein-Barr virus infection with IgM VCA was also detected (Figure 1, 2, 3).





**Figure 1, 2, 3 MRI (October 2008)** - Multiple round and oval-shaped lesions of different sizes, hyperintense in T2 and FLAIR present in the white matter and around the lateral ventricles. Some lesions in the white matter conflate in plaques. Ventricles are of normal shape

All cases were treated according to the last *Clinical Practice Guidelines by The Infectious Diseases Society of America* with ceftriaxon 2g/day for 21 days followed by doxycycline 100 mg/day for 21 days. Treatment was well tolerated except the case mentioned before who presented biliary sludge during the last cure interrupted after 14 days. In all cases neuroprotective adjunctive therapy was considered: group B vitamins, Q10 coenzyme, piracetam and in the five confirmed MS cases either beta interferon or metilprednisolon were used. All cases improved during hospitalization: better stamina, less muscular weakness and paresthesia, more vigorous walking and no vertigo.

## Discussions

The confirmation of late NB is difficult because specific criteria may be lacking: absent or minimal CSF modifications, tick exposure and erythema migrans might be absent. Culture of *B. burgdorferi* is sensitive only in cutaneous infections and it is not routinely used, PCR technique of blood is not well standardized therefore not recommended and detection of antibodies is not essential since seronegative patients with borreliosis are frequently mentioned. The diagnosis is often based on clinical judgment rather than on well defined clinical and validated laboratory criteria [8,13,24]. The most important for the diagnosis of MS are also clinical criteria being the first joint feature to late NB. MS is an autoimmune demyelinating disease and the counterpoint of the presence of *B. burgdorferi* infection demonstrated by serology is false positivity but in any of our cases no positivity was encountered for syphilis or other serologic examinations.

We have to mention that the inclusion of the 41 and 58kDa band as one of the specific bands was introduced in our clinic only in 2008. Line blot assays have a higher sensitivity especially for IgM antibodies: 73,8% compared to 40% Western-blot [1,24]. In all cases EIA was positive for IgM, being confirmed through immunoblot test in 4 of the 7 tests performed. This is in contrast with Agosta's results that found IgG seropositivity (with WB confirmation) in all cases of late NB with neuroimaging indistinguishable from MS [7]. IgM positivity might be speculated as being a mark of active infection. Since mainly in Europe there is great concern towards seronegative late Lyme disease a new scoring system of the WB test was revisited with increase in sensitivity (total number of bands, specific bands, their intensity and 41kDa band presence) [13]. Our suggestion is that the limits of WB test might explain some discordant enzyme immunoassay vs. WB. The MRI is considered as being essential in MS diagnosis but, in NB, structural and functional neuroimaging is in assessment. Occult modifications in white and grey matter are present in patients with NB demonstrating the tissue damage: small hypointense lesions in T1, hyperintense on T2 and fluid-attenuated inversion recovery (FLAIR) being hyper or hypometabolic in functional MRI (fluoro-deoxyglucose- PET) [2,10,21]. The abnormal lesions are located in the cortex, subcortex, deep white matter, subcortical mainly in the frontal and temporal lobes and in the basal nuclei. In recent studies upon patients with NB presenting focal symptoms, neuroimaging demonstrated the presence of multiple sclerosis-like lesions. In stark contrast to what is found in MS, the measures for tissue integrity were normal in patients with NB [21]. Structural and functional MRI evaluation demonstrates the delayed resolution of white matter changes following the treatment of NB [10,12]. Triple association MS-cerebral lymphoma-NB is described as well as NB mimicking cerebral lymphoma [4,12]. In the above presented case NB is highly probable, MS was previously confirmed and the MRI lesions mimicked cerebral lymphoma as in other reports [4]. We appreciate that in the five confirmed cases of MS, relapses were linked to reactivation of the *B. burgdorferi* infection suggested by IgM positivity and the benefits of the treatment. In the other five cases of possible MS, diagnosis is challenging since the same minimal MRI abnormalities are described. Delayed resolution of cerebral tissue is observed in NB and only repeated structural

and functional neuroimaging can demonstrate the benefits of the etiologic treatment. Clearly, the demyelinating lesions in MS are not reversible in stark contrast with NB where normalized cerebral imaging occurs after therapy [24]. After etiologic treatment clear benefits are to be seen in 1-3 months but sometimes symptoms persist, labeled as post-Lyme disease [23]. The question is if *B. burgdorferi* infection triggers the MS manifestations or if NB mimics MS. Further fundamental, epidemiological and clinical studies are needed.

## Conclusions

The diagnosis of MS and NB are difficult because of remarkably similar clinical and neuroimaging features. The infectious etiology of MS remains probable and in patients diagnosed with possible MS it is reasonable to evaluate *B. burgdorferi* infection in order to ensure etiologic treatment.

## References

1. **Aberer E.** Lyme borreliosis-an update JDDG, 2007, band 5 CME 406-13.
2. **Agosta F, Rocca MA, Benedetti B, Capra R, Cordioli C, Filippi M;** MR Imaging Assessment of Brain Cervical Cord Damage in Patients with Neuroborreliosis; *AJNR Am J Neuroradiol* 27:892-94.
3. **Agüero-Rosenfeld ME, Wang G, Schwartz I, Wormser GP;** Diagnosis of Lyme Borreliosis. *Clin Microbiol Rev*, 2005; 18(3): 484-509.
4. **Batinac T, Petranovic D, Zamolo G, Petranovic D, Ruzic A,** Lyme Borreliosis And Multiple Sclerosis Are Associated With Primary Effusion Lymphoma; *Med Hypotheses*. 2007;69(1):117-9. Epub 2007 Jan 2.
5. **Brorson O, Brorson SH, Henriksen RH, Skogen PR, Schoyen R.** Association between multiple sclerosis and cystic structures in cerebrospinal fluid. *Infection* 2001;29,315-9.
6. **Cairns V, Godwin J;** Post-Lyme Borreliosis Syndrome: A Meta-Analysis Of Reported Symptoms. *Int J Epidemiol* 2005; 34:1340-1345.
7. **Evans R, Malvin S, O. Ho-Yen D,** Audit of the Laboratory Diagnosis of Lyme Disease in Scotland, *Journal of Medical Microbiology*, 2005, , 54, 1139-1141.
8. **Feder HM, Johnson BJ, O'Connell S, Ad Hoc International Lyme Disease Group;** A Critical Appraisal Of „Chronic Lyme Disease.“ *N Engl J Med* 2007; 357:1422-1430.
9. **Fritzsche M,** Chronic Lyme Borreliosis At The Root Of Multiple Sclerosis-Is A Cure With Antibiotics Attainable?; *Medical Hypotheses*, 2005, 64, 438-448.
10. **Greer DM, Schaefer PW, Plotkin SR, Hasserjian RP, Steere AC,** Case 11-2007: A 59-Year-Old Man with Neck Pain, Weakness in the Arms, and Cranial-Nerve Palsies; *N Engl J Med* 2007;356:1561-70.
11. **Gunther G, Haglund M;** Tick-Borne Encephalopathies: Epidemiology, Diagnosis, Treatment And Prevention. *CNS Drugs* 2005; 19:1009-1032.
12. **Halperin JJ;** Central Nervous System Lyme Disease. *Curr Neurol Neurosci Rep* 2005; 5:446-452.
13. **Hunfeld KP, Fingerle V, Stanek G, Daghofer E, Bra-de V, Wilske B, Peters H.** European multicentre study for evaluation of a new enzyme immunoassay for serodiagnosis of Lyme borreliosis and other tick-borne diseases. *10<sup>th</sup> Intl. Conference on Lyme Borreliosis and other tick-borne diseases*, September 11-15, 2005, Vienna, Austria.
14. **Hurley RA, Taber KH,** Acute and Chronic Lyme Disease: Controversies for Neuropsychiatry, *Journal of Neuropsychiatry and Clin Neurosci*, 2008, <http://neuro.psychiatryonline.org/cgi/content/full/20/1/iv>.
15. **Kuiper H,** Clinical Spectrum And Incidence Of Neuroborreliosis In Netherlands; *Ned Tijdschr Geneesk*, 2004 Apr 3;148(14): 670-673.
16. **Pachner AR, Steiner I;** Lyme Neuroborreliosis: Infection, Immunity, And Inflammation. *Lancet Neurol* 2007; 6:544-552.
17. **Sastre-Garriga J, Tinitore M, Rovira A, Nos C et al.** Specificity of Barkhof Criteria in Predicting Conversion to Multiple Sclerosis When Applied to Clinically Isolated Brainstem Syndromes: *Arch Neurol*, 2004, 61:222-224.
18. **Singh SK, Girschick HJ;** Lyme Borreliosis: From Infection To Autoimmunity; *Clin Microbiol Infect* 2004, 10(7): 598-614.
19. **Sormani MP, Tintorè M, Rovaris M, Rovira A, Vidal X, Bruzzi P, Filippi M, Montalban X.;** Will Rogers phenomenon in multiple sclerosis, *Ann Neurol*. 2008;64(4):428-433.
20. **Steere AC, Coburn J, Glickstein L.** The emergence of Lyme disease. *J Clin Invest* 2004;113:1093-101.
21. **Steinbach JP, Melms A, Skalej M, Dichgans J,** Delayed Resolution Of White Matter Changes Following Therapy Of B Burgdorferi Encephalitis, *Neurology*, 2005; 64: 758-759.
22. **Vesna Brinar,** Multiple Sclerosis, [www.ifcc.org-eJIFCC](http://www.ifcc.org-eJIFCC) 2006,17(3), Paper 10.
23. **Walther EU, Seelos K, Bise K, Mayer M, Straube A.** Lyme Neuroborreliosis Mimicking Primary CNS Lymphoma. *Eur Neurol* 2004;51:43-5.
24. **Wormser GP, Dattwyler RJ, Shapiro ED, et al.** The Clinical Assessment, Treatment, And Prevention Of Lyme Disease, Human Granulocytic Anaplasmosis, And Babesiosis: Clinical Practice Guidelines By The Infectious Diseases Society Of America. *Clin Infect Dis* 2006;43:1089-134.